

Werner Schupp, Julia Haubrich, Mario Klingberg, Wolfgang Boisserée, Un-seob Sim, Hoon Kim

Shape memory aligners: A new dimension in aligner orthodontics



Werner Schupp

KEY WORDS 3D printing, aligner orthodontics, direct aligner printing, Graphy, in-office aligners, interdisciplinary treatment, shape memory, tooth movement

To overcome the limitations of the conventional vacuum thermoforming manufacturing process, the method of direct 3D printing of aligners has been developed. This presents more advantages than simply avoiding a two-step process, whereby the model needs to be printed first before the aligners are thermoformed. The shape memory function offers new and improved biomechanical options. This article presents the new direct 3D printed aligner material from Graphy (Seoul, South Korea) and a patient example demonstrating the course of treatment with the new material.

Introduction

Aligner orthodontics has been an integral part of orthodontics for over 20 years¹⁻²³. The initial biomechanical limita-

tions posed by the aligner technique have now largely been overcome²⁴⁻⁴¹, and aligner orthodontics is becoming increasingly important within orthodontic treatment techniques worldwide^{20,42-47}. It remains a component of academically based dentistry and cannot be delegated to laypeople, as is currently being suggested by companies with huge advertising budgets for economic reasons. Further developments in software, printing technology and now the direct aligner printing process are offering significantly more possibilities, especially for in-office aligner technology, which is becoming increasingly important^{36-38,48-50}. The direct printing process using shape memory plastic (TC-85, Graphy, Seoul, South Korea) and the properties of this material are described in the present study.

Digital light processing

As a 3D printing technology, digital light processing (DLP) has continuously proven itself to be a promising option with the capability to construct highly complex geometries rapidly and with microscale precision⁵³.

Vat photopolymerisation (VPP) is an additive manufacturing technology that involves a liquid vat of photopolymer resin and an ultraviolet (UV) light source. When exposed to UV light, the photosensitive resin undergoes polymerisation and cures into a solid form. Based on this stereolithographic principle, the VPP printer projects UV light onto a resin surface in the desired shape of a mask such that only

Werner Schupp, Dr med dent
Private practice, Cologne, Germany

Julia Haubrich, Dr med dent
Private practice, Cologne, Germany

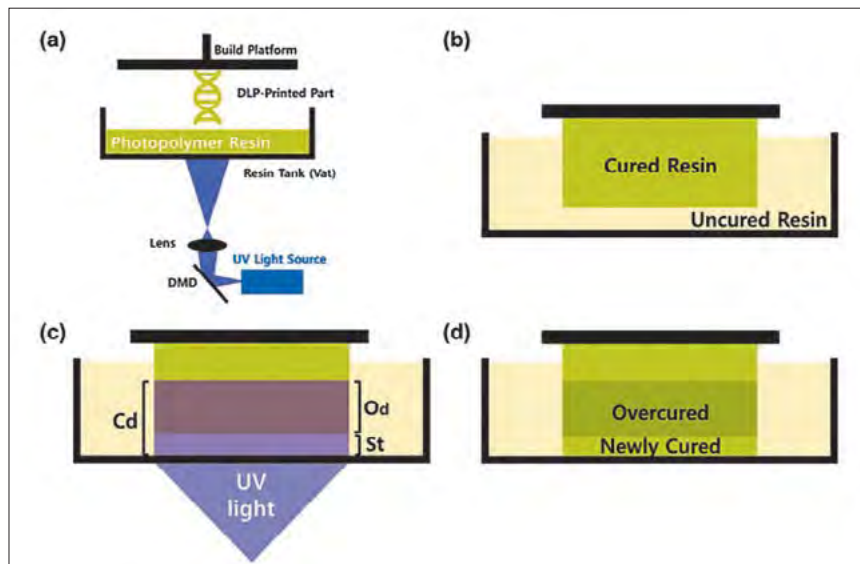
Mario Klingberg
Dental Technician, Private practice, Cologne, Germany

Wolfgang Boisserée, Dr med dent
Private practice, Sürth, Germany

Un-seob Sim
CEO, Graphy, Seoul, South Korea

Hoon Kim, PhD
Senior Researcher, R&D Centre, Graphy, Seoul, South Korea

Correspondence to: Dr Werner Schupp, Hauptstrasse 50, 50996 Cologne, Germany. Email: schupp@schupp-ortho.de



Figs 1a-d DLP: the structure of the DLP printer and the overcuring mechanism of the photosensitive material during the lamination process. (a) A schematic representation of a bottom-up DLP printing process. (b) Printing state before UV irradiation for adhesion of a new layer. (c) As UV light penetrates to cured depth (Cd), the uncured fresh resin undergoes curing, whereas the already cured resin undergoes additional polymerisation, or "overcuring", where the overcured depth (Od) is determined by the UV light energy, resin absorption coefficient and slice thickness (St). (d) Successful adhesion of a new layer as a result of sufficient crosslinking between the layers due to the overcuring effect. (Reprinted from Lee et al⁵¹ with permission.)

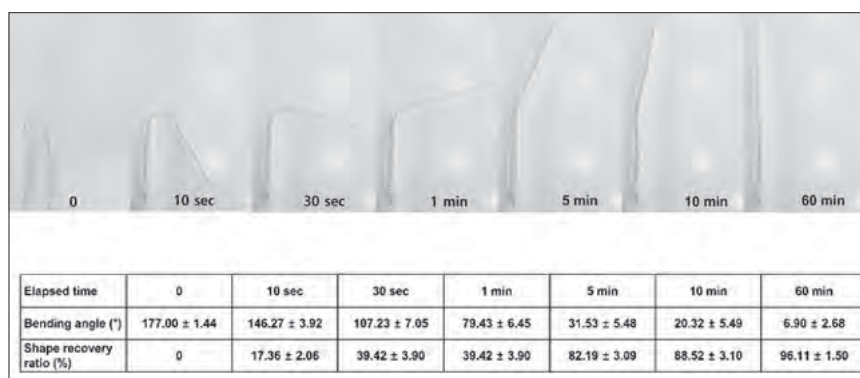


Fig 2 Shape memory effect and shape recovery ratio over time of TC-85 (N = 6). (Reprinted from Lee et al⁵² with permission.)

a specified region solidifies. After each layer, the build platform with the attached printed part moves in the z-direction and UV light is focused on the next layer, and printing continues in this way in a layer-by-layer fashion (Fig 1). DLP printers have five main printing parameters that have significant effects on mechanical properties: slice thickness, UV exposure intensity, exposure time, printing direction and post curing. Among these parameters, there are multiple correlations that must be considered to achieve optimal part quality⁵¹.

Properties of the direct aligner printing material

After being bent at 80°C, the cooled TC-85 specimen remained folded (Fig 2); however, the specimens recovered their original shape over time at 37°C. Rapid recovery of more than 50% of the bending was observed within the first minute, but the shape recovery rate decreased gradually

thereafter. Approximately 90% of the deformation was recovered in 10 minutes, and the shape recovery ratio was 96% after 60 minutes. Under the same conditions, polyethylene terephthalate glycol (PETG) maintained its deformed shape and showed no shape recovery.

In clinical practice, since aligners are manufactured using dental casts of patients with different anatomical characteristics such as tooth size, dental arch size, alveolar bone height and palatal vault depth, irregular thickness changes may occur. It has also been demonstrated that within one aligner, the thickness varies for each region, such as the incisors, molars and edentulous areas. Since the thickness of the aligners is the factor that has the greatest influence on the orthodontic force applied to the teeth, irregular thickness makes it difficult for clinicians to predict how the clear aligners will perform and what the treatment outcomes will be. If the aligners are manufactured by 3D




Fig 3 Performance of direct printed aligners compared to that of conventional aligners. (Reproduced by permission of Graphy.)

printing, it is possible to decrease the variation in thickness and increase the predictability of treatment outcomes, and the fit of the aligner to the tooth is better than with thermoformed aligners (Fig 3). Moreover, if the technology is developed further, the thickness can be modified based on the type of tooth movement and region, thus potentially increasing the efficiency of the treatment in clinical practice. In a virtual articulator with controlled virtual treatment simulation (VTS), it is even possible to simulate the occlusion with both aligners in situ. Currently, 3D printed aligners made from TC-85 material are generally manufactured using a DLP-type 3D printer with layer thickness set to 100 μm . In addition, the change in physical properties and accuracy based on the angle of the output of the aligner is not significant⁵⁴.

Residual resin remaining on the surface of the printed aligners is removed using a soft scraper and alcohol. Finally, they are post-cured under N_2 with UV light using a post-curing chamber. Post curing must take place in an oxygen-free environment in an N_2 atmosphere to complete the reaction on the surface of the resin. This is because oxygen is a radical scavenger that inhibits radical reactions. If post curing is carried out in the presence of oxygen, the surface chemical crosslink density of the resin will record a lower level compared to the inside of the sample. These conditions are closely related to the biological stability and maintenance of resin transparency in the oral environment⁵⁵.

The yield strength and elastic modulus were significantly higher in PETG than in TC-85, whereas the elastic range was significantly larger in TC-85 (4.65%) than in PETG (3.92%). With conventional aligners manufactured from thermoplastic materials, it is advisable to perform tooth

movement of 0.25 to 0.33 mm per step and activate the aligners once every 2 weeks for effective orthodontic tooth movement. These results indicate that owing to the higher flexibility and larger elastic range of clear aligners manufactured using TC-85, more tooth movement can be performed per step without causing permanent deformation. Studies are required to evaluate these initial findings.

Regarding the stress relaxation and creep behaviour, at 37°C, when a load was applied for 60 minutes, TC-85 initially showed rapid stress relaxation; after 13 cyclic loads, a residual static force of 1.00 N was observed. Although stress relaxation occurred in PETG, the amount of relaxation was smaller than that of TC-85, with a residual static force of 11.39 N after 13 cyclic loads. The stress relaxation and creep behaviour of TC-85 offers these aligners greater flexibility and an improved fit after being worn in the oral cavity. In addition, by constantly applying a light force to the teeth, it is possible to induce a physiological tooth movement and reduce the discomfort experienced by the patient. In clinical practice, an orthodontic force of 0.098 to 1.180 N is recommended depending on the type of tooth movement. Excessive force may have side effects on the teeth and surrounding tissues, including root resorption, and an orthodontic force applied beyond the patient's pain threshold will result in discomfort. The static force shown by TC-85 at 37°C was appropriate to apply an orthodontic force; however, the large initial static force of TC-85 may cause discomfort to the patient when inserting and removing the aligner. Also, since a large amount of stress relaxation occurs, the predictability of the aligner may deteriorate. In TC-85, as the load cycle was repeated, the rate of strain recovery increased and the residual static force after relax-

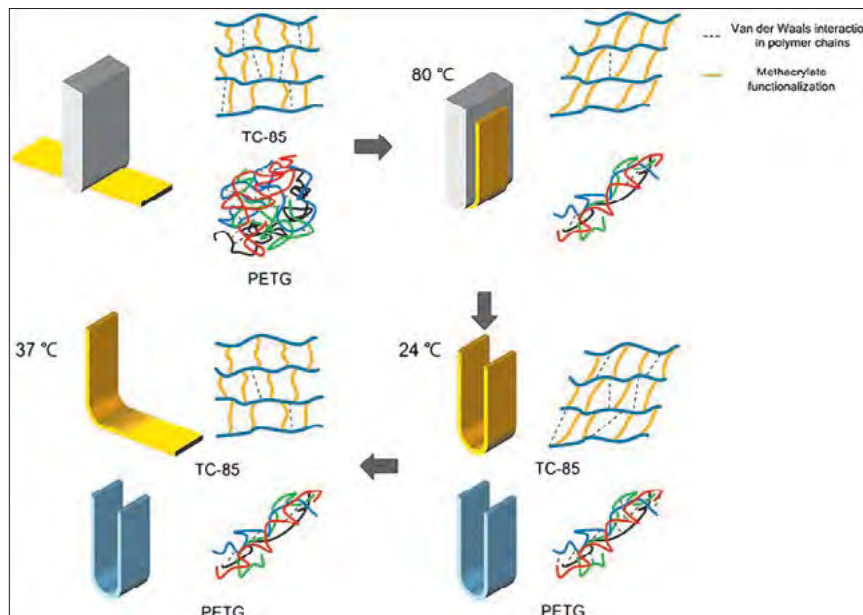


Fig 4 Shape memory property test procedure and mechanism; yellow and blue specimens indicate TC-85 and PETG, respectively. (Reprinted from Lee et al⁵² with permission.)

ation also showed a gradual increasing pattern. This difference in behaviour is due to the fact that thermoplastic and photocurable resins have completely different structures on a molecular level. For thermoplastic resins, the polymer chains maintain the linear structure at room temperature with van der Waals interactions. On the other hand, for photocurable resins like Graphy's direct aligner resin, oligomers and monomers within the resin form 3D network structures as the material undergoes radical polymerisation. Because the van der Waals interaction occurs simultaneously with the network structure, the structure can remember and return to its original shape even if the material is deformed above the glass transition temperature. Thus, the photocurable direct aligner material has shape memory properties.

As shown in Fig 4, the thermoplastic polymer material (PETG) becomes soft and permanently deformed at high temperatures and cannot return to its original shape. The interaction between polymer chains in photocurable resin crosslinked with a 3D network structure (TC-85) also decreases as the temperature rises, and the degree of freedom of movement of the chains increases, which causes the material to become softer and more flexible; however, unlike PETG, TC-85 can return to its original shape, which is memorised by the chemical network structure. Because of these characteristics, the TC-85 aligner can apply orthodon-

tic force continuously to teeth under normal body temperature conditions without a loss of force due to deformation of the aligner that may be caused by external force during usage. Even if the aligner experiences deformation, the original printed shape and rigidity are restored at 37°C.

The crystallisation in the amorphous portion of the material by tensile stress may induce this behaviour (Figs 5 and 6). In PETG, the residual static force and strain recovery rate remain relatively constant even after repeated cyclic loads. In aligners, force decay occurs because of the viscoelastic properties of the material and the permanent deformation caused by repeated insertion of the aligners. It has been previously shown that a three-point bending test on aligner materials resulted in a 10% to 17% decrease in static force after repeated loads. The creep behaviour of TC-85, with the gradually increasing static force under cyclic loads, may be more advantageous in respect to clinical performance as force decay is reduced, maintaining the orthodontic force of the aligners.

TC-85 showed a slight stress relaxation, and after 13 cyclic loads, the static force was 0.12 N, whereas PETG exhibited rapid stress relaxation and showed low static force with 0.01 N. At 80°C, the interaction between the polymer chains of both materials is weakened so their storage modulus and elasticity decrease; however, owing to the crosslinked structure of TC-85, it is highly stable. As such, it

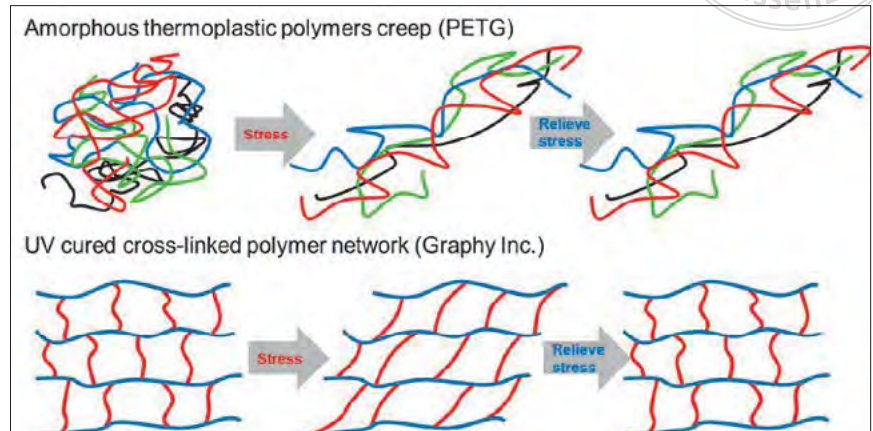
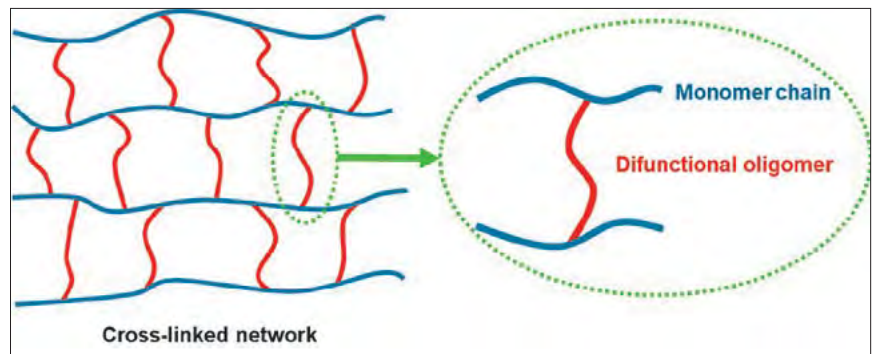


Fig 5 Photocurable resin for 3D printing. (Modified from Lee et al⁵² with permission.)

Figs 6 Shape memory polymer: stress relaxation speed of TC-85 > PETG. The recovery pattern to deformation is different, and TC-85 shows a major recovery in viscoelastic properties. PETG has a strong tendency towards elastic recovery but shows weak viscoelastic behaviour at the end of recovery. Strong orthodontic force can lead to orthodontic trauma and cause the patient to feel orthodontic pain. (Modified from Lee et al⁵² with permission.)

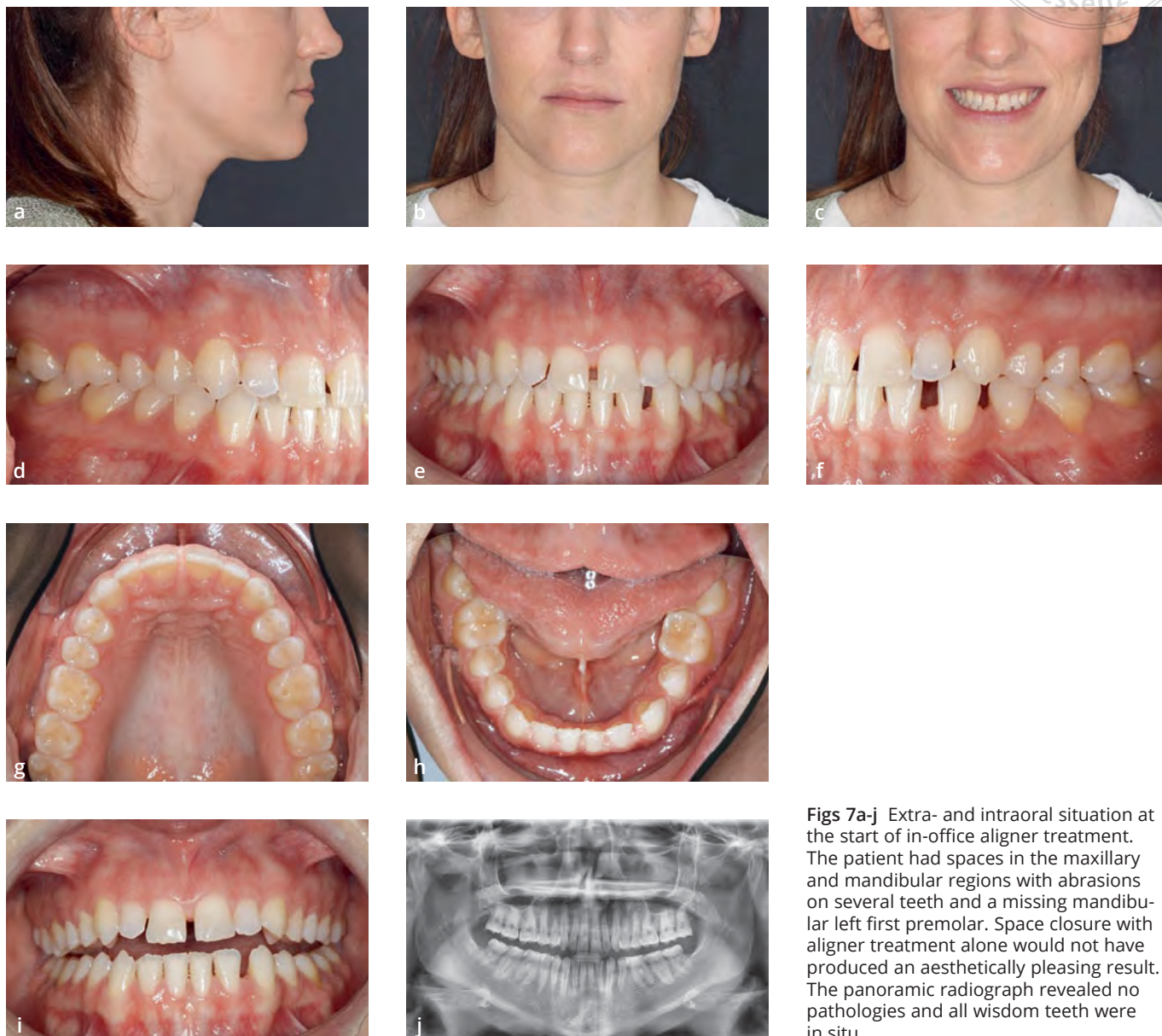

was able to maintain a constant stiffness while also retaining the static force and strain recovery patterns after repeated loads. PETG, a non-crosslinked polymer, showed a pattern of gradual increase in static force under cyclic loads and the strain recovered to a negative value. At 80°C, the interactions between the polymer chains of PETG were weakened, allowing the movement of chains; thus, thermal shrinkage was caused.

TC-85 has geometric stability at high temperatures without thermal shrinkage as demonstrated, which can be advantageous in clinical practice. Manufacturing clear aligners from TC-85 makes hygiene management and disinfection of aligners feasible. Generally, microorganisms begin to colonise the clear aligner surface 6 hours after insertion, and the deposited biofilm prevents full coverage of the dentition with the clear aligners, thus resulting in unaccomplished tooth movement; however, clinicians advise patients not to clean or disinfect their aligners at high temperatures because thermoplastic materials, such as PETG, deform.

A thermorheological study indicated that *Streptococcus mutans* and related lactic acid bacteria, the major causative organisms of dental caries, are inactivated at temperatures above 60°C. Further studies are required to verify that washing aligners at high temperatures does not affect their performance and has a disinfectant effect in clinical practice.

Owing to the shape memory property of TC-85, aligners can apply orthodontic forces to the teeth constantly at a normal body temperature without force decay caused by aligner deformation. This also presents an advantage when patients wear their aligners. Before applying them, patients can immerse them in warm water to make them flexible, which can reduce discomfort when wearing them and provide a better fit. Even if the aligner is deformed along the dentition, its original printed shape and stiffness will be recovered at 37°C. Thus, the aligners can apply a constant orthodontic force to the teeth⁵².

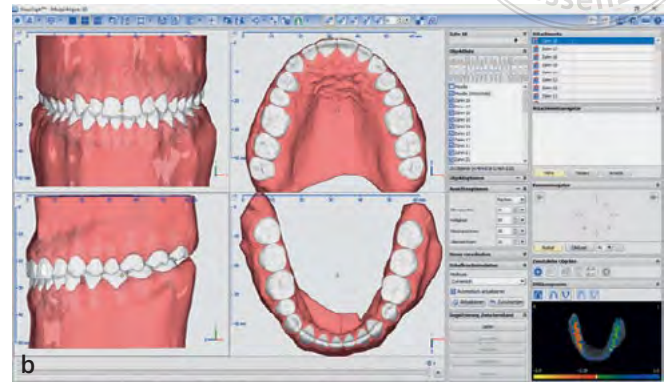
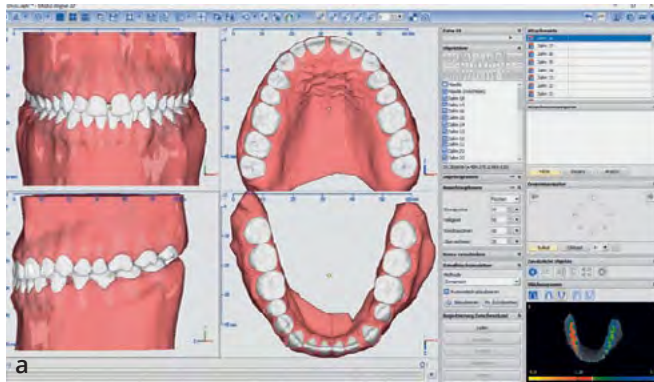


Figs 7a-j Extra- and intraoral situation at the start of in-office aligner treatment. The patient had spaces in the maxillary and mandibular regions with abrasions on several teeth and a missing mandibular left first premolar. Space closure with aligner treatment alone would not have produced an aesthetically pleasing result. The panoramic radiograph revealed no pathologies and all wisdom teeth were in situ.


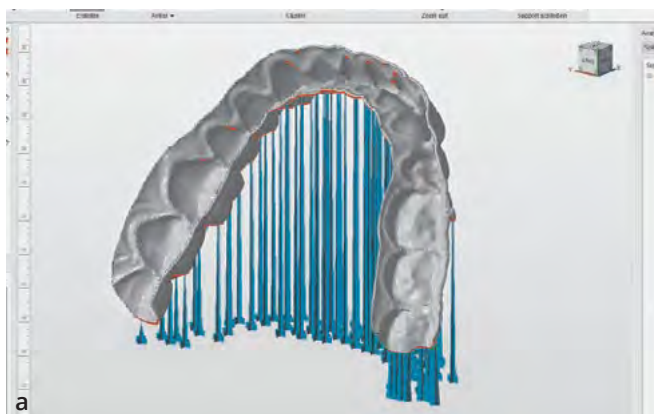
Advantages of direct 3D printing of aligners and the shape memory effect

3D printing of aligners offers multiple advantages, namely the following:

- shape memory effect;
- the original printed shape and stiffness are recovered in the mouth at 37°C each time;
- the aligner has equal extension/thickness at each point;
- the approach is sustainable due to avoidance of plastic;
- layer thickness is modified depending on the force required on each individual tooth;
- greater tooth movement is possible per step;
- TC-85 is more flexible and has a larger elastic range;
- the production process is simpler and less finishing is required, especially of the edges;
- hygiene is improved as TC-85 can be cleaned at 60°C to 80°C;
- the fit of the aligner to the tooth is optimal with almost no gap;
- discomfort and pain are reduced.



Figs 8a-b (a) Initial scan transferred into OnyxCeph software and (b) the planned outcome after six steps with spaces remaining distal to the maxillary right lateral incisor and a bigger gap mesial to the mandibular left second premolar, which was planned to receive restorative treatment after aligner treatment.



Figs 9a-b Production procedure for Graphy direct aligners. Support pins were added in Rapid Shape Netfabb software (Heimsheim, Germany). The layer thickness was 0.5 mm.

Case report

A 35-year-old woman attended the present authors' office with spaces in both anterior regions and a missing mandibular left first premolar, which had led to migration of the mandibular left canine distally and the mandibular left posterior teeth mesially, resulting in asymmetrical spaces and a Class II relationship on the left side. The patient did not demonstrate any signs of craniomandibular dysfunction. Several teeth showed abrasions. The panoramic radiograph exhibited no pathologies with all wisdom teeth in situ. The treatment plan included orthodontic treatment with the in-office aligner system. Space closure mesially of the mandibular left canine and increase of space distally of the same tooth was planned in the VTS, followed by restorative dentistry with closure of the remaining spaces and re-

shaping of the maxillary and mandibular incisors (Fig 7). Figure 8 presents the initial scan transferred into OnyxCeph software (Image Instruments, Chemnitz, Germany) showing the planned outcome after six steps with spaces remaining distal to the maxillary right lateral incisor and an increased gap mesial to the mandibular left second premolar (planned for later restorative treatment). In Fig 9, one step of the production procedure for the Graphy direct aligners is shown, and support pins were added in Rapid Shape Netfabb software (Heimsheim, Germany). Figure 10 shows the aligner immediately after the printing process and before light curing. The finalised Graphy direct aligners are shown in situ in Fig 11. The longer aligner margins made it possible to ensure major crown coverage. No use of attachments was planned in this treatment. After four steps and 8 weeks of treatment, the patient's Graphy direct aligners still dis-

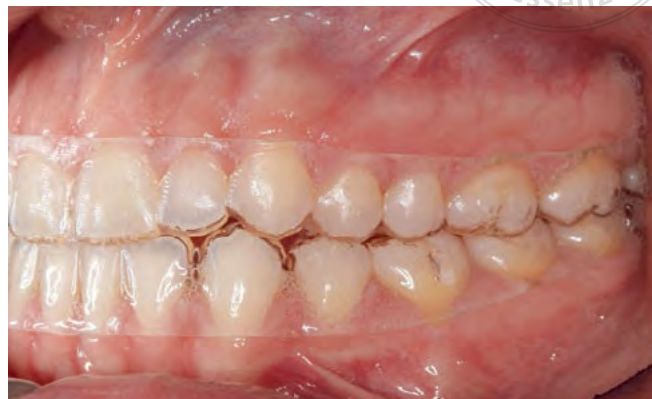
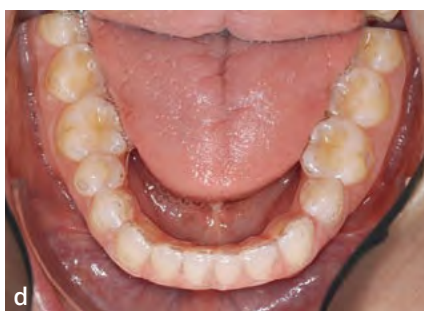
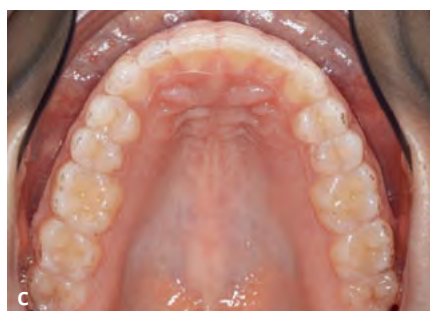
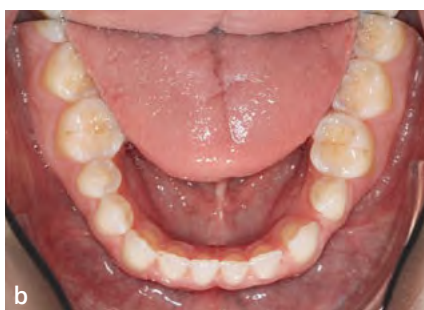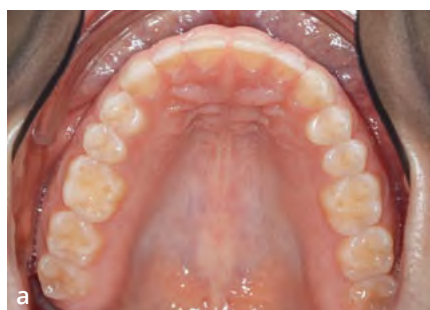Fig 10 (left) Graphy direct printed aligner with support pins immediately after printing.

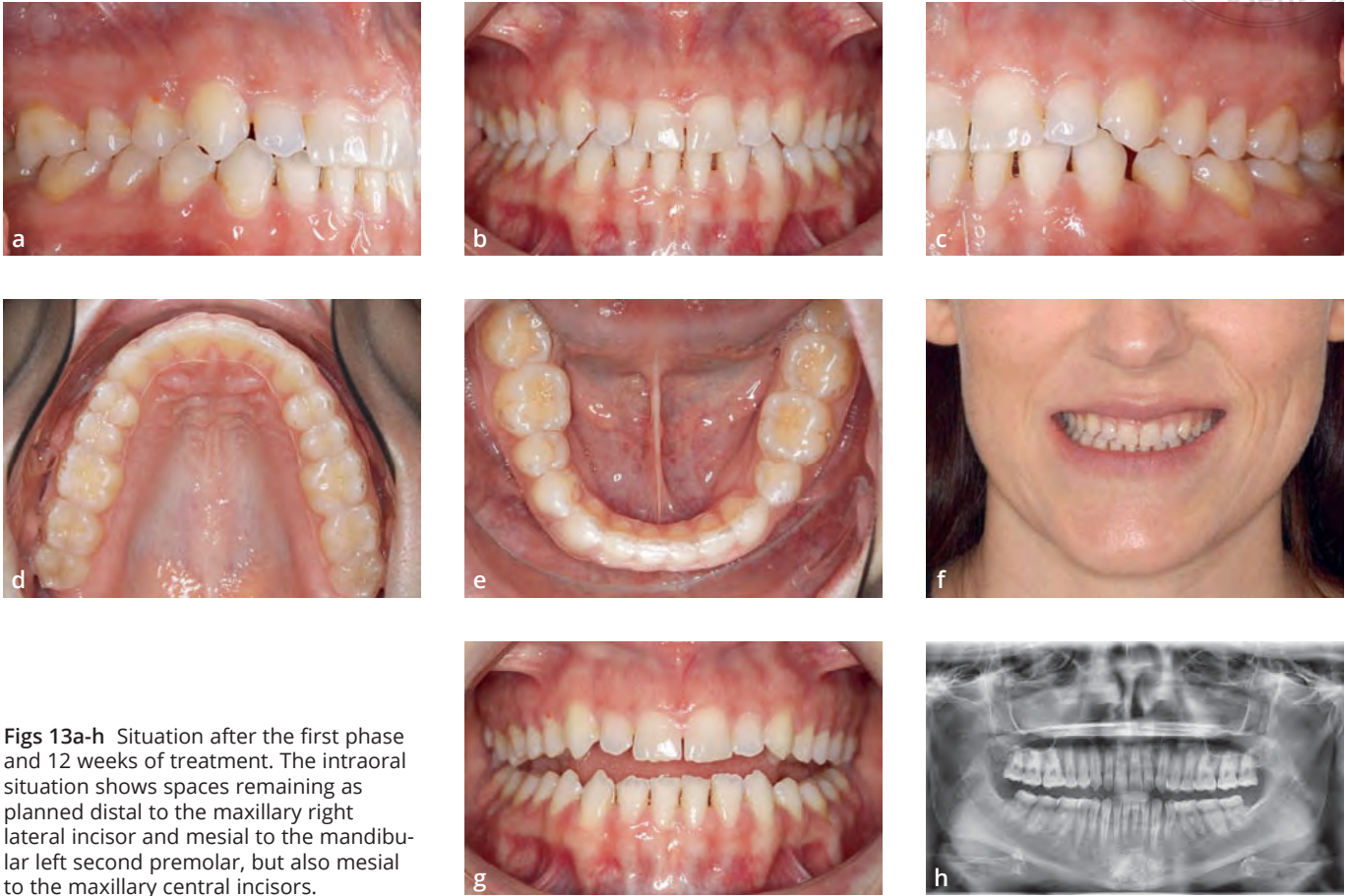Fig 11 (right) Finished Graphy direct aligner in situ, showing longer margins to ensure increased crown coverage for optimal biomechanics.



Figs 12a-d Situation during treatment with (a and b) aligner step four and (c and d) well-fitting Graphy direct aligners in situ.

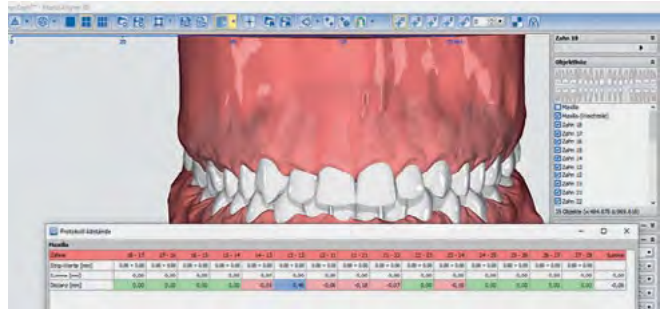
played an optimal fit (Fig 12). Figures 13a-h demonstrate the situation after the first phase and 12 weeks of treatment. The intraoral situation shows spaces remaining distal to the maxillary right lateral incisor and mesial to the mandibular left second premolar as planned. A residual gap remained mesial to the maxillary central incisors, even though overcorrection of space closure of -0.18 mm mesial to these teeth was planned in the software (Fig 14).

There are two possible reasons for the remaining gap mesial to the maxillary central incisors. The first of these is that the material was not accurate. This would imply that none of the other movements would have taken place either; however, this contradicts the success of the movements that were achieved with the same material in the second phase. The second reason is that the proximal region was not precise in the scan. It is common knowledge

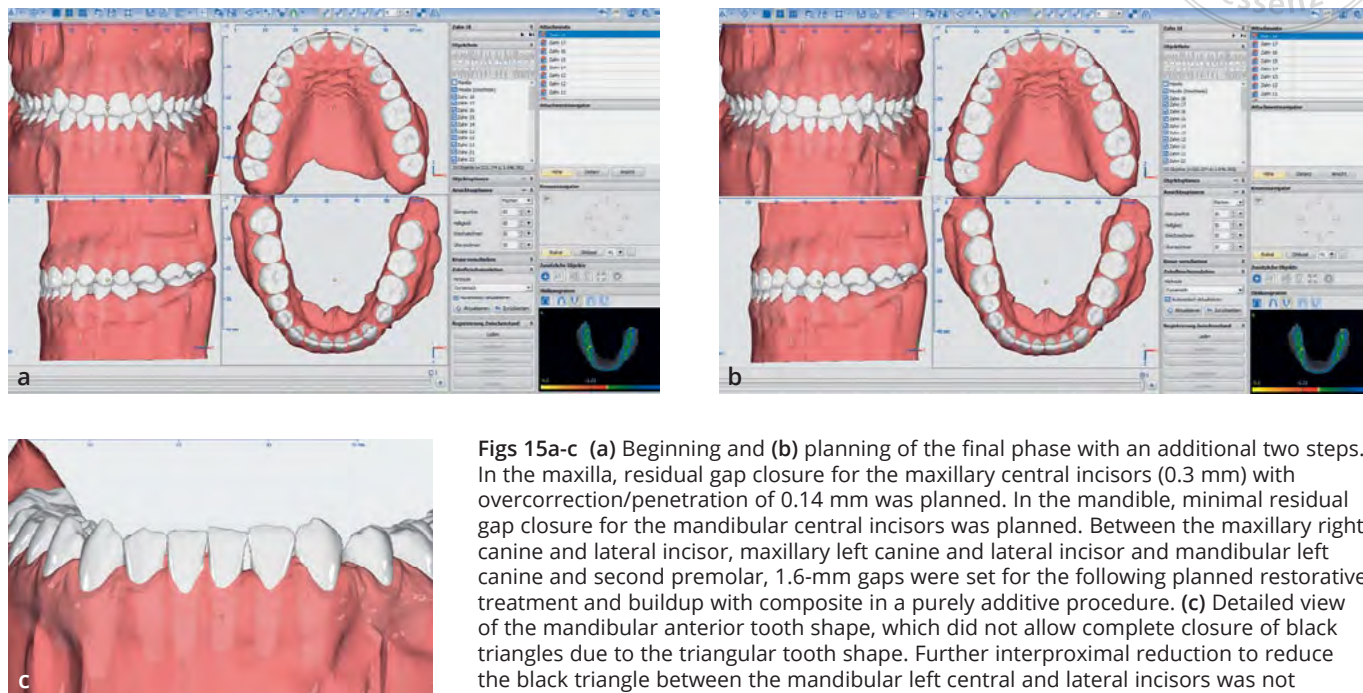


Figs 13a-h Situation after the first phase and 12 weeks of treatment. The intraoral situation shows spaces remaining as planned distal to the maxillary right lateral incisor and mesial to the mandibular left second premolar, but also mesial to the maxillary central incisors.

Fig 14 Detail of the anterior teeth situation after the first phase with a gap remaining mesial to the maxillary central incisors even though -0.18 mm overcorrection of mesialisation was planned for these teeth in the OnyxCeph VTS. *According to FDI notation.



Maxilla																
Tooth*	18-17	17-16	16-15	15-14	14-13	13-12	12-11	11-21	21-22	22-23	23-24	24-25	25-26	26-27	27-28	Total
Amount of interproximal reduction (mm)	0.00 + 0.00	0.00 + 0.00	0.00 + 0.00	0.00 + 0.00	0.00 + 0.00	0.00 + 0.00	0.00 + 0.00	0.00 + 0.00	0.00 + 0.00	0.00 + 0.00	0.00 + 0.00	0.00 + 0.00	0.00 + 0.00	0.00 + 0.00	0.00 + 0.00	0.00
Total (mm)	0.00	0.00	0.00	0.00	0.00	0.00	0.00	0.00	0.00	0.00	0.00	0.00	0.00	0.00	0.00	0.00
Distance (mm)	0.00	0.00	0.00	0.00	-0.05	0.46	-0.06	-0.18	-0.07	0.00	-0.160	0.00	0.00	0.00	0.00	-0.06



Figs 15a-c (a) Beginning and (b) planning of the final phase with an additional two steps. In the maxilla, residual gap closure for the maxillary central incisors (0.3 mm) with overcorrection/penetration of 0.14 mm was planned. In the mandible, minimal residual gap closure for the mandibular central incisors was planned. Between the maxillary right canine and lateral incisor, maxillary left canine and lateral incisor and mandibular left canine and second premolar, 1.6-mm gaps were set for the following planned restorative treatment and buildup with composite in a purely additive procedure. (c) Detailed view of the shape of the mandibular anterior tooth, which did not allow complete closure of black triangles due to the triangular tooth shape. Further interproximal reduction to reduce the black triangle between the mandibular left central and lateral incisors was not planned to avoid further reduction of the small tooth size. Thus, closure of the black triangle mesial to the mandibular left central incisor with an additive composite technique was planned after aligner treatment.

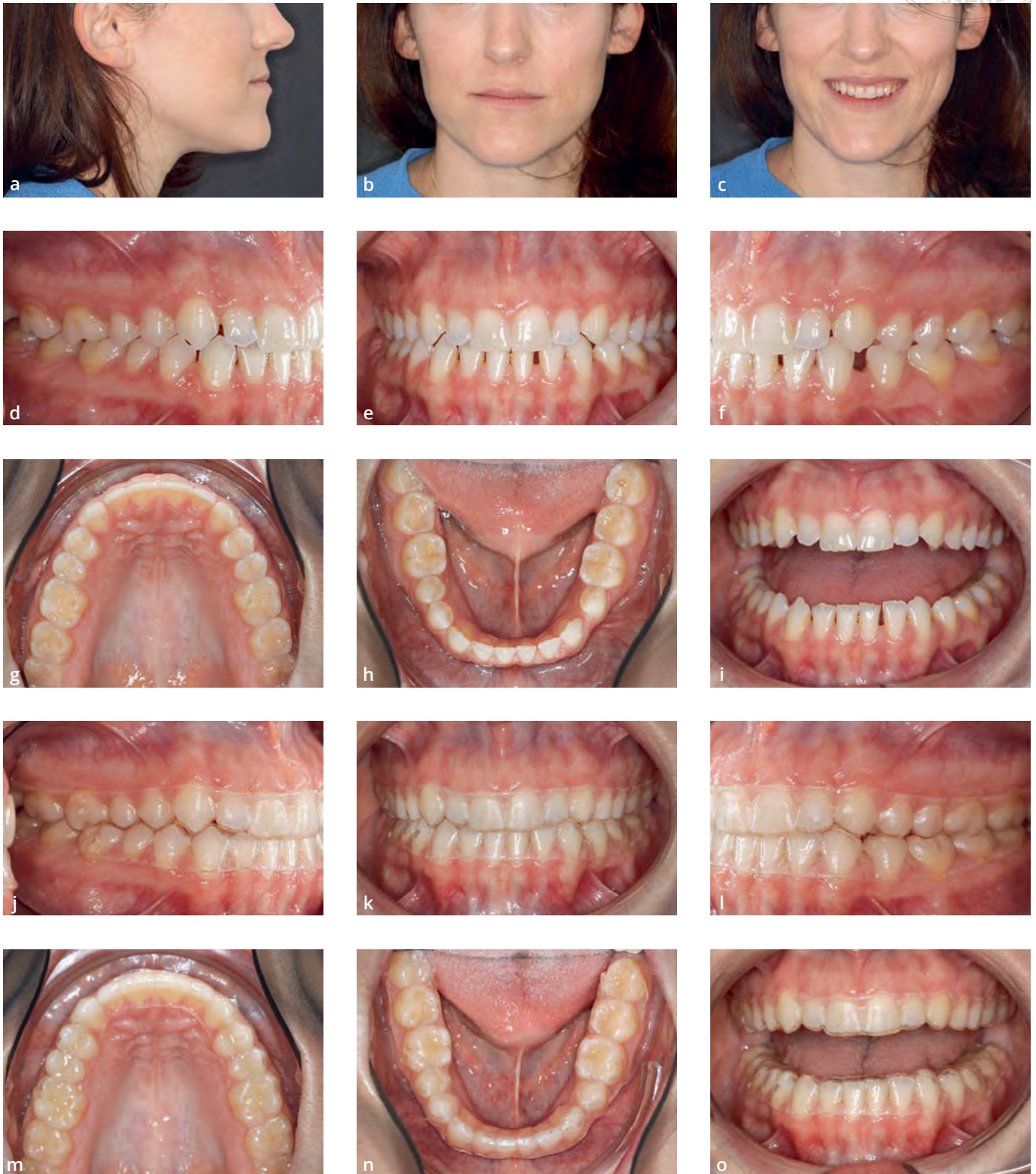that the calculation of approximal area by means of algorithms still has room for improvement.

A new scan was taken and again transferred into Onyx-Ceph (Fig 15). Figure 15 shows the start and planned outcome of the final phase with an additional two steps. In the mandible, minimal residual space closure was planned to increase the space mesial to the mandibular second premolar to 1.6 mm, which was due to be restored at a later stage. In the maxilla, residual gap closure for the maxillary central incisors (0.30 mm) with an overcorrection/penetration of 0.14 mm was planned. Between the maxillary right and left canines and lateral incisors, remaining spaces were planned virtually for the subsequent planned restorative treatment and buildup with composite. Figure 15c shows a detailed view of the shape of the mandibular anterior tooth, which was triangular and thus did not permit complete closure of the black triangle. No further interproximal reduction was planned to reduce the black triangle between the mandibular left central and lateral incisors to prevent the already small tooth from becoming even smaller. Thus, closure of the black triangle mesial to the mandibular left lateral incisor with an additive composite technique was planned after aligner treatment.

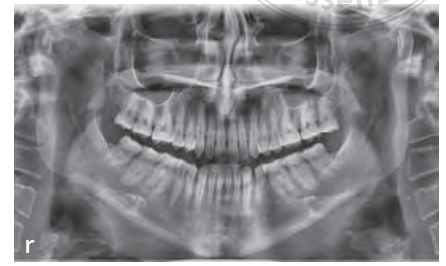
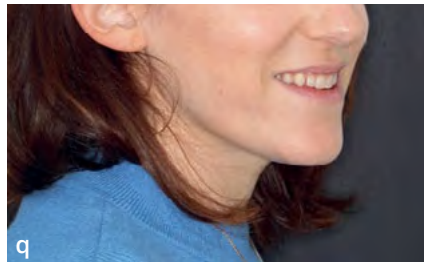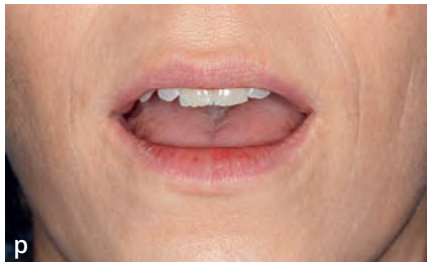Figure 16 demonstrates the result after a total treatment time of 14 weeks with Gephy direct aligner material. Figures 16i to m show the last Gephy aligner in situ, displaying a good fit. The treatment objectives were achieved without the use of attachments. The patient was referred to dental practitioner Dr Wolfgang Boisserée, Cologne, who restored and reshaped the teeth using the additive composite technique only to allow a minimally invasive procedure. In Fig 17, the final extraoral and intraoral situations are shown 1 week after gingivectomy was performed with a laser and scalpel on the maxillary anterior teeth and composite restorations (Enamel Plus HFO, Micerium, Avegno, Italy) on the maxillary right and left canines and lateral and central incisors, and the mandibular left first premolar and left and right canines and lateral and central incisors.

Retention was performed with a removable aligner in the maxilla worn at night and a fixed lingual retainer (0.215-inch five-stranded steel wire) from the mandibular left first premolar to the mandibular right first premolar.

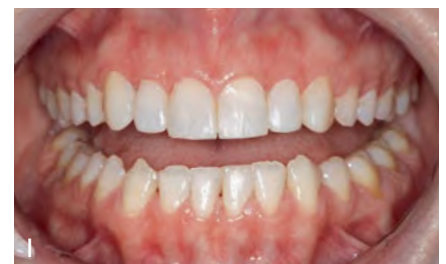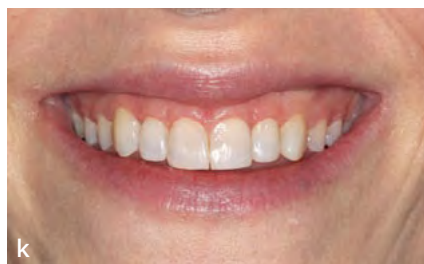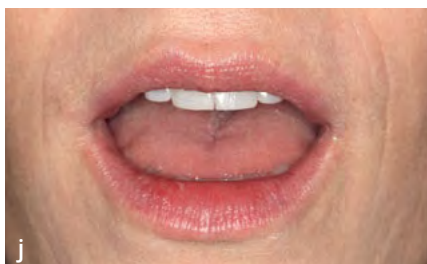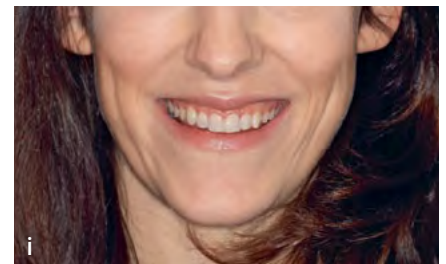
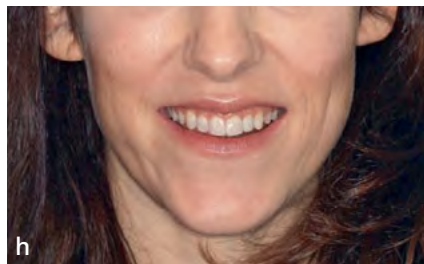
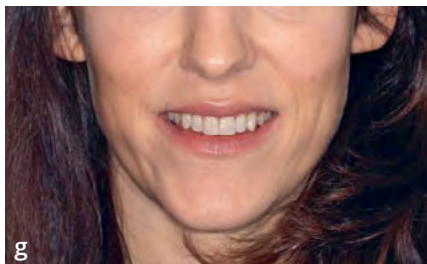
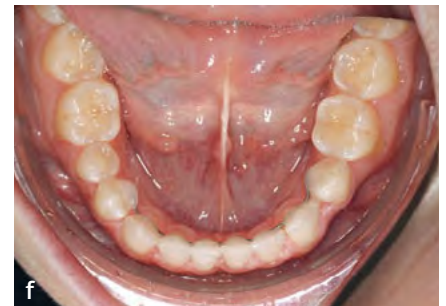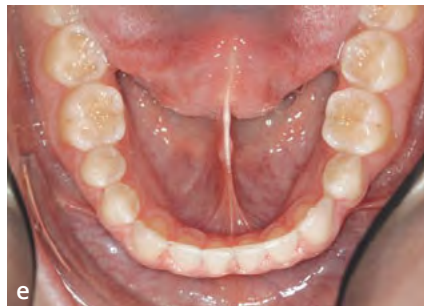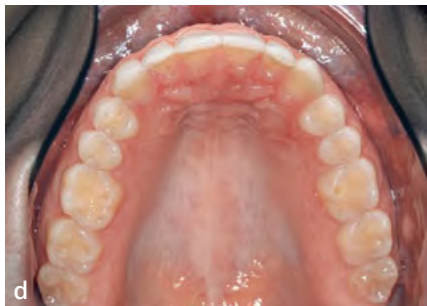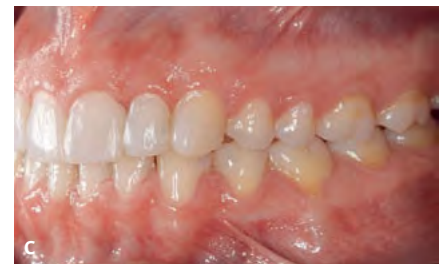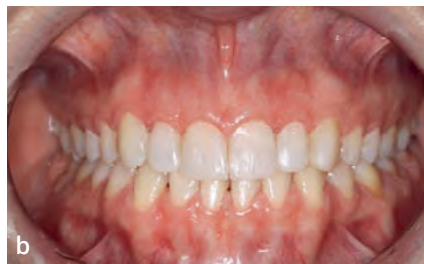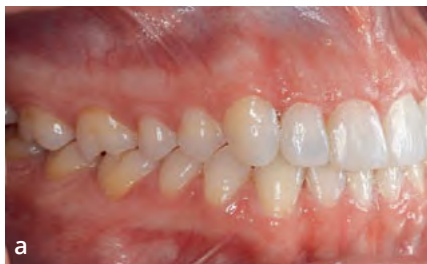A comparison of the initial situation with the final orthodontic and restorative outcome is shown in Fig 18.



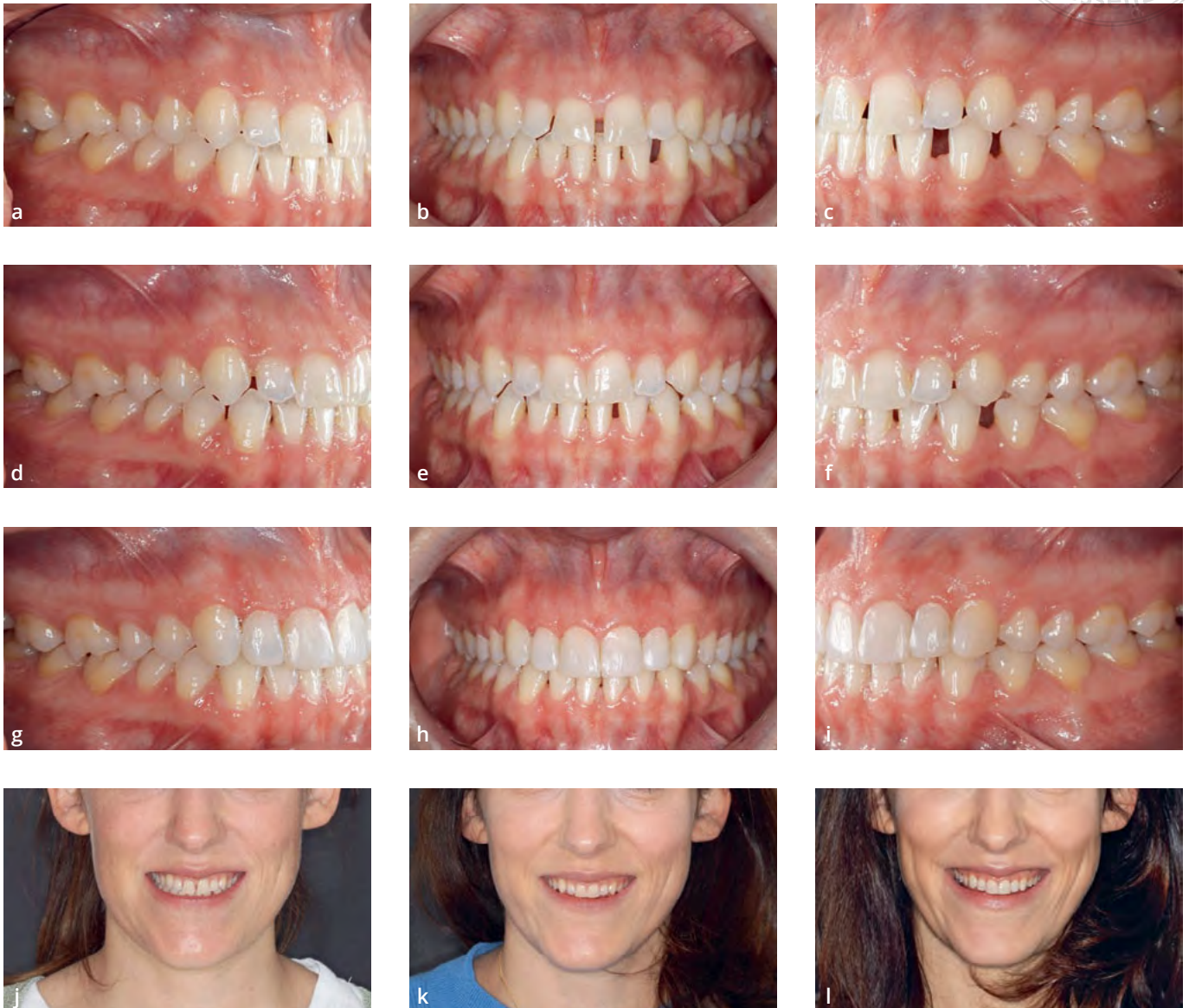Figs 16a-r Final extra- and intraoral situation after treatment with in-office direct Graphy aligners. The treatment was performed with longer straight aligner margins, but with no attachment on the teeth for additional anchorage. The final panoramic radiograph showed no pathologies.



Figs 16a-r (cont.)



Figs 17a-l Extra- and intraoral situation after restoration of anterior teeth with composite (Enamel Plus HFO) and 1 week after gingivectomy on the maxillary anterior teeth (Dr Wolfgang Boisserée, Cologne). Retention was performed with a removable aligner in the maxilla and a fixed lingual retainer (0.215-inch five-stranded steel wire) from the mandibular left first premolar to the mandibular right first premolar.



Figs 18a-l Comparison (a-c) before and (d-f) after orthodontic treatment with in-office direct Graphy aligners. (g to i) After restoration with composite on the maxillary and mandibular anterior teeth and 1 week after gingivectomy (Dr Wolfgang Boisserée, Cologne). (j to l) Smile before and after interdisciplinary treatment.

Discussion

Aligner treatment has been an integral part of orthodontics for over 20 years now. Improvements in technology and software but also knowledge held by treating doctors due to treatment experience and scientific publications have made aligner therapy a valuable alternative to fixed appliance treatment. Various developments have occurred, such as scanning and printing technology and software for in-office aligner orthodontics, which has made technology for the

latter more user-friendly and treatment outcomes more predictable. On the other hand, some developments made by aligner companies have been more for promotional purposes. In-office aligner orthodontics has become integral to many practices, allowing doctors to implement aligner treatment in the office if desired, without needing to outsource it. Biomechanical knowledge of aligner orthodontics and technical knowledge of the production and mechanical properties of in-office aligners are indispensable elements of this procedure and continue to be a *sine qua non*.

After the first aligner materials, monolayers, multilayer materials of different thicknesses were developed, which can be used for many tooth movements and are superior to the former. The latest technical development is 3D printed shape memory technology. The recently released TC-85 material by Graphy not only offers the advantage of not needing to print a model, which helps to reduce plastic waste and make orthodontics more sustainable, but also makes tooth movements more predictable and precise due to the new material properties such as the shape memory effect.

Conclusion


Direct printed aligner technology has established itself and the first experiments with the new material show promising results. The potential advantages offered by the material, such as aligner thickness and shape memory, provide a new way of delivering orthodontic treatment with aligners. Further evidence-based studies are required to confirm these initial positive findings.

Declaration

Un-seob Sim is an employee of Graphy, Seoul, South Korea. Hoon Kim is an employee of the R&D Centre, Graphy, Seoul, South Korea. All other authors declare there are no conflicts of interest relating to this study.

References

- Bastendorf KD, Strafela-Bastendorf N. Aligner orthodontics and preventive dentistry. *J Aligner Orthod* 2021;5:259–265.
- Castroflorio T, Garino F, Parrini S, Deregibus A. Case reports on mandibular advancement with clear aligners in growing subjects. *J Aligner Orthod* 2018;2:125–139.
- Chang S, Schupp W, Haubrich J, Yeh W, Tsai M, Tabancis M. Aligner therapy in treating bimaxillary dentoalveolar protrusion. *J Aligner Orthod* 2019;3:277–301.
- Choi D, Ngan P, Shipley T, Mukdadi OM, Xiang J. Effect of micro-osteoperforations on orthodontic tooth movement with clear aligner treatment. *J Aligner Orthod* 2019;3:43–53.
- Couchat D. Prevention of tooth impaction with Invisalign: A case report. *J Aligner Orthod* 2017;1:59–64.
- Couchat D. Traction of impacted teeth with the Invisalign System. *J Aligner Orthod* 2018;2:53–58.
- Dayan W, Aliaga-Del Castillo A, Janson G. Open-bite treatment with aligners and selective posterior intrusion. *J Clin Orthod* 2019;53:53–54.
- Eliseo A, Fiorillo G. Temporary anchorage devices (TADs) and Invisalign: A combination that can be used to meet aesthetic expectations in the orthodontic treatment of adult patients. *J Aligner Orthod* 2019;3:15–27.
- Giancotti A, Garino F, Mampieri G. Use of clear aligners in open bite cases: An unexpected treatment option. *J Orthod* 2017;44:114–125.
- Haubrich J, Schupp W. Invisalign treatment in early years to avoid potential extraction treatments - Case reports. *J Aligner Orthod* 2018;2:39–52.
- Haubrich J, Schupp W. Orofacial orthopaedics: Background and possibility of combination with aligners. *J Aligner Orthod* 2020;4:111–142.
- Honn M, Goz G. A premolar extraction case using the Invisalign system. *J Orofac Orthop* 2006;67:385–394.
- Krieger E, Seiferth J, Marinello I, et al. Invisalign(R) treatment in the anterior region: Were the predicted tooth movements achieved? *J Orofac Orthop* 2012;73:365–376.
- Lombardo L, Colonna A, Carlucci A, Oliverio T, Siciliani G. Class II subdivision correction with clear aligners using intermaxillary elastics. *Prog Orthod* 2018;19:1–8.
- Ma H, Feng Y, Pu P, Ren Y, Gu Z. Angelalign treatment of an adult with excessive overjet and a missing mandibular premolar: A case report. *J Aligner Orthod* 2019;3:93–105.
- Mah JK. Clear aligner therapy (CAT) in two hyperdivergent patients. *J Aligner Orthod* 2019;3:107–118.
- Malekian K, Parrini S, Garino F, Deregibus A, Castroflorio T. Mandibular molar distalization with clear aligners in Class III patients. *J Aligner Orthod* 2019;3:7–14.
- Ojima K, Dan C, Watanabe H, Kumagai Y. Upper molar distalization with Invisalign treatment accelerated by photobiomodulation. *J Clin Orthod* 2018;52:675–683.
- Schupp W, Funke J, Haubrich J, Boisserée W. Follow-up treatment after initial splint therapy. *J Aligner Orthod* 2019;3:147–164.
- Schupp W, Haubrich J (eds). *Aligner Orthodontics*. Berlin: Quintessenz, 2015.
- Schupp W, Haubrich J, Ojima K, Dan C, Kumagai Y, Otsuka S. Accelerated Invisalign treatment of patients with a skeletal Class III. *J Aligner Orthod* 2017;1:37–57.
- Yezdani AA. Transparent aligners: An invisible approach to correct mild skeletal class III malocclusion. *J Pharm Bioallied Sci* 2015;7 (suppl 1):S301–S306.
- Zheng M, Liu R, Ni Z, Yu Z. Efficiency, effectiveness and treatment stability of clear aligners: A systematic review and meta-analysis. *Orthod Craniofac Res* 2017;20:127–133.
- Bock H, Bock J, Karbach F, et al. Material properties and first clinical applications of CA Pro, a novel aligner foil. *J Aligner Orthod* 2022;6: 163–181.
- Cai Y, He B, Yang X, Yao J. Optimization of configuration of attachment in tooth translation with transparent tooth correction by appropriate moment-to-force ratios: Biomechanical analysis. *Biomed Mater Eng* 2015;26(suppl 1):S507–S517.
- Cortona A, Rossini G, Parrini S, Deregibus A, Castroflorio T. Clear aligner orthodontic therapy of rotated mandibular round-shaped teeth: A finite element study. *Angle Orthod* 2020;90:247–254.
- Cowley DP, Mah J, O'Toole B. The effect of gingival-margin design on the retention of thermoformed aligners. *J Clin Orthod* 2012;46:1: 697–702.
- El-Bialy T. Rethinking the bioprogressive technique for Class II correction with clear aligners. *J Aligner Orthod* 2019;3:119–127.
- Elkholy F, Lapatki BG. Recommendation of a novel film-thickness sequence, 0.4, 0.5 and 0.75 mm, for aligner systems. *J Aligner Orthod* 2018;2:295–304.



30. Elkholy F, Mikhael B, Schmidt F, Lapatki BG. Mechanical load exerted by PET-G aligners during mesial and distal derotation of a mandibular canine: An in vitro study. *J Orofac Orthop* 2017;78:361-370.
31. Elkholy F, Panchaphongsaphak T, Kilic F, Schmidt F, Lapatki BG. Forces and moments delivered by PET-G aligners to an upper central incisor for labial and palatal translation. *J Orofac Orthop* 2015;76:460-475.
32. Elkholy F, Schmidt F, Jager R, Lapatki BG. Forces and moments delivered by novel, thinner PET-G aligners during labiopalatal bodily movement of a maxillary central incisor: An in vitro study. *Angle Orthod* 2016;86:883-890.
33. Elkholy F, Schmidt F, Jager R, Lapatki BG. Forces and moments applied during derotation of a maxillary central incisor with thinner aligners: An in-vitro study. *Am J Orthod Dentofacial Orthop* 2017;151:407-415.
34. Fujita Y, Kimura H, Yanagisawa W, Inou N, Maki K. Experimental verification of finite element analysis for a thermoplastic orthodontic aligner. *Showa Univ J Med Sci* 2014:139-147.
35. Gabsi I, Dallel I, Benattia A, Tobji S, Amor A. An experimental study on forces delivered by aligners: Effect of material type and beverages. *J Aligner Orthod* 2021;5:267-278.
36. Gao L, Wichelhaus A. Forces and moments delivered by the PET-G aligner to a maxillary central incisor for palatal tipping and intrusion. *Angle Orthod* 2017;87:534-541.
37. Krey K, Behyar M, Hartmann M, Corteville F, Ratzmann A. Behaviour of monolayer and multilayer foils in the aligner thermoforming process. *J Aligner Orthod* 2019;3:139-145.
38. Krey K, Hartmann M, Schicker P, Corteville F, Eigenwillig P. Complete digital in office workflow for aligner treatment with a fused filament fabrication (FFF) 3D printer: Technical considerations and report of cases. *J Aligner Orthod* 2019;3:195-204.
39. Liu Y, Hu W. Force changes associated with different intrusion strategies for deep-bite correction by clear aligners. *Angle Orthod* 2018;88:771-778.
40. Ojima K, Dan C, Watanabe H, Kumagai Y, Nanda R. The biomechanics of aligner orthodontics in open-bite cases. *J Clin Orthod* 2019;53:699-712.
41. Simon M, Keilig L, Schwarze J, Jung BA, Bourauel C. Forces and moments generated by removable thermoplastic aligners: Incisor torque, premolar derotation, and molar distalization. *Am J Orthod Dentofacial Orthop* 2014;145:728-736.
42. Azaripour A, Weusmann J, Mahmoodi B, et al. Braces versus Invisalign®: Gingival parameters and patients' satisfaction during treatment: A cross-sectional study. *BMC Oral Health* 2015;15:1-5.
43. Chaudhari PK, Zere E. Letter to the Editor: Future of aligner orthodontics in the digital age. *J Aligner Orthod* 2018;1:11-12.
44. Fujiyama K, Honjo T, Suzuki M, Matsuoka S, Deguchi T. Analysis of pain level in cases treated with Invisalign aligner: Comparison with fixed edgewise appliance therapy. *Prog Orthod* 2014;15:1-7.
45. Krey K, Abu-Tarif A, Haubrich J, Elkholy F, Mah J, Schupp W. Artificial intelligence in orthodontics: Part 3 – Potential limitations and pitfalls. *J Aligner Orthod* 2022;6:153-162.
46. Mah J. How aligner systems became the world's orthodontic appliance. *J Aligner Orthod* 2020;4:87-90.
47. Piergentili M, Bucci R, Madariaga ACP, Martina S, Rongo R, D'Antò V. Pain and discomfort associated with labial multibracket appliances vs clear aligners. *J Aligner Orthod* 2019;3:205-212.
48. Chaudhari P, Turkyilmaz I, Zere E, Sokhi R. In-house aligners for correction of relapse in mandibular incisor alignment. *J Aligner Orthod* 2021;5:217-223.
49. Salazar T. In-office thermoplastic aligner workflow. *J Aligner Orthod* 2021;5:123-130.
50. Schupp W, Haubrich J. In-office aligner treatment. *Inf Orthod Kieferorthop* 2020;52:289-300.
51. Lee J, Kim H, Kim H, et al. Average-Accumulated Normalized Dose (A-AND) predicts ultimate tensile strength and elastic modulus of photopolymer printed by vat photopolymerization. *Addit Manuf* 2022;55:102799.
52. Lee SY, Kim H, Kim HJ, et al. Thermo-mechanical properties of 3D printed photocurable shape memory resin for clear aligners. *Sci Rep* 2022;12:1-10.
53. Kim H, Khan TA, Ryu KH, Sohn IS, Kim HJ. Nanocomposite materials for 3D printing. In: Ahmed W, Maciel MAM (eds). *Applications and Industrialisation of Nanotechnology*. Manchester: One Central Press, 2022:91-118.
54. Tahayeri A, Morgan M, Fugolin AP, et al. 3D printed versus conventionally cured provisional crown and bridge dental materials. *Dent Mater* 2018;34:192-200.
55. Simič R, Mandal J, Zhang K, Spencer ND. Oxygen inhibition of free-radical polymerization is the dominant mechanism behind the "mold effect" on hydrogels. *Soft Matter* 2021;176:6394-6403.