



Julia Haubrich, Werner Schupp

Invisalign treatment in early years to avoid potential extraction treatments – case reports



Julia Haubrich

Key words aligner orthodontics, case reports, ClinCheck Software, extractions, interceptive treatment, Invisalign, lack of space, mixed dentition, teen treatment

In patients with premature loss of baby teeth and insufficient retention of spaces, the Leeway space can be reduced due to undesired neighbouring tooth migration and space could become insufficient for the eruption of all permanent teeth. Various orthodontic treatment options may be used to reopen spaces and avoid potential extractions in the permanent dentition. One option is treatment with the Invisalign Teen System, which allows an almost invisible and comfortable way of treating patients, with fewer potential side effects than with conventional fixed appliances. Several examples will be presented in this article to show how Invisalign treatment procedures in early years can avoid potential extraction treatments.

Introduction

Since the introduction of Invisalign onto the US market in 1999 and into European countries in 2001, there have been various developments helping to bring aligner orthodontics

to a standard orthodontic treatment. In the past, orthodontic therapies with the Invisalign technique, such as natural space closure, crowding¹, crossbite², Class II treatment³, deep bite⁴, and open bite treatments^{5,6} have been described in the literature⁷. Extractions are possible with the aligner system^{8,9}, as well as movements such as distalization or torque^{10,11}. Aligner therapy can be used in pre-restorative orthodontic treatments¹²⁻¹⁴, surgical pre-treatments¹⁵ and also in complex craniomandibular disorder (CMD) treatments^{14,16-18}. Its combination with skeletal anchorage, such as mini-screws, further widens the range of complex treatments^{19,20}. Therefore, the Invisalign System has become a common treatment option in orthodontics, avoiding potential side effects that may arise during fixed orthodontic treatment with multibracket technique, for instance decalcifications, enamel abrasion due to bracket contact, or gingival inflammations due to hypersensitivity to nickel. Patients treated with the Invisalign System show better periodontal health²¹⁻²³ and greater satisfaction during orthodontic treatment than those who are treated with fixed orthodontic appliances^{24,25}. Other studies explored the microbiological and periodontal changes occurring in adolescents over 12 months of orthodontic therapy with removable aligners and with fixed appliances. Results showed that teenagers treated with removable appliances displayed better compliance with oral hygiene, less plaque, and fewer gingival inflammatory reactions than their peers with fixed appliances²⁶. Additionally, it was shown that during the in-

Julia Haubrich, Dr. med. dent.
 Fachpraxis für Kieferorthopädie, Gemeinschaftspraxis, Hauptstraße 50,
 50996, Köln

Werner Schupp, Dr. med. dent.
 Fachpraxis für Kieferorthopädie, Gemeinschaftspraxis, Hauptstraße 50,
 50996, Köln

Correspondence to: Dr Julia Haubrich
 E-Mail: haubrich@schupp.ortho-de

itial stages of treatment²⁷, the Invisalign treatment is less painful than the edgewise appliance.

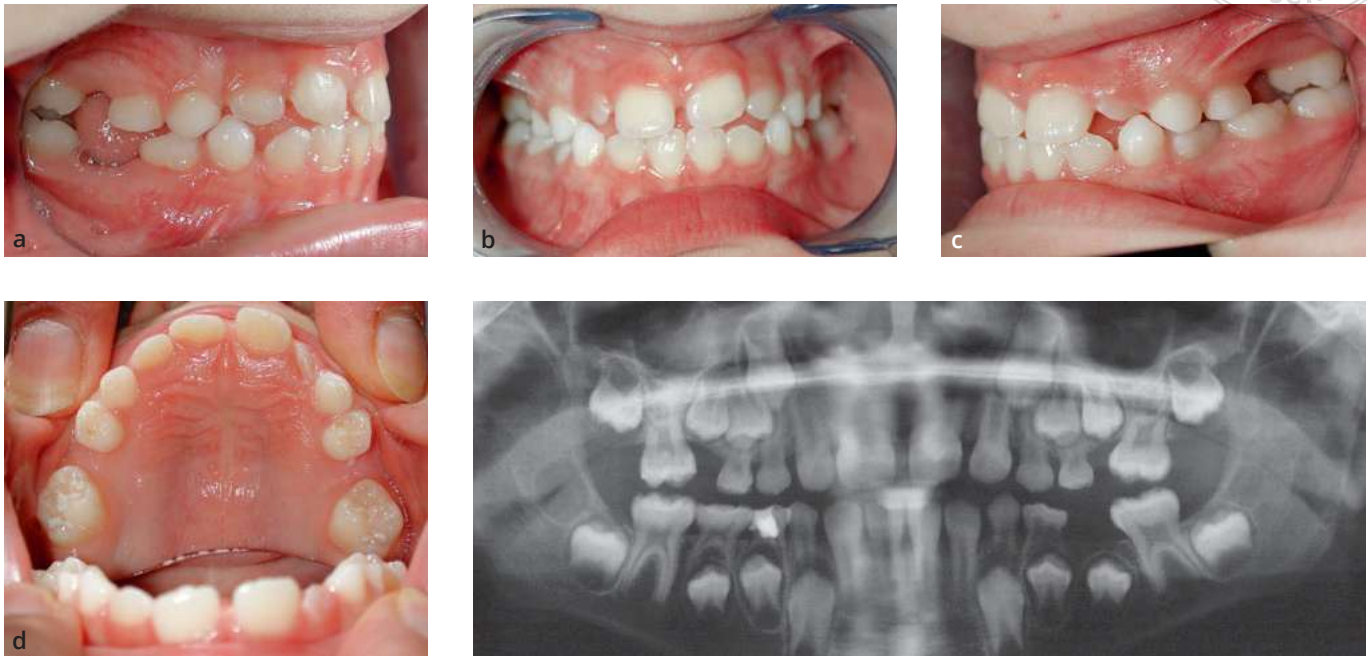Enormous differences in orthodontic extraction frequency can be found worldwide. A group of orthodontists in Michigan described the range of extractions for orthodontic treatment as being from 5% to 87%²⁸. The world dental literature for orthodontic extraction frequency varies within a range of 6.5% to 83.5%²⁹. In a study by Baumrind³⁰, crowding was cited as the first reason in 49% of decisions to extract, followed by incisor protrusion (14%), the need for profile correction (8%), Class II severity (5%) and achievement of stable results (5%). The prevalence of orthodontic extraction varies greatly and appears to have decreased over past decades. In particular this applies to Caucasian patients. Asian patients benefit from extraction therapy from anaesthetic view, as they tend to show protruded lip positions and crowding, which might lead to better aesthetic results with extractions. Xu showed that extraction treatment increases the inclination of the chin and reduces protrusion of the lower lip compared with non-extraction treatment³¹. The orthodontic therapy of Caucasian patients often requires the opposite aspect. These patients do not want to flatten their existing profile and lip configuration, but to maintain or even improve lip aesthetics. If patients are treated with the incisor position as a reference point, independent of extraction or non-extraction, treatment outcomes show no significant changes in the appearance of the soft tissue³². A study by Kim and Gianelly³³ showed that in a comparison of extraction vs non-extraction cases, the arch width is not decreased at a constant arch depth because of extraction treatment, and smile aesthetics are the same in both groups of patients.

Treatment stability is an important objective in orthodontics and often an argument for performing an extraction therapy. However, the stability of aligned teeth is variable and largely unpredictable. A post-retention relapse of mandibular anterior crowding in patients treated without mandibular premolar extraction was 1.95 mm or 26.54%, 5 years post-retention³⁴. According to Zafarmand, extraction and non-extraction protocols are two different methods of treatment, but they seem to show a similar tendency to incisor relapse³⁵. After serial extraction of first premolars and orthodontic therapy with standard edgewise technique, 22 of 30 patients (73%) demonstrated unsatisfactory mandibular anterior alignment after a minimum of 10 years

post-retention³⁶. Another retrospective study compared the treatment outcome of mandibular incisor extraction, premolar extraction and non-extraction treatment³⁷. It has been shown, that orthodontic treatment without extraction has a better treatment outcome than the four first premolar extraction and single mandibular incisor extraction protocols in Class I patients with moderate to severe mandibular anterior crowding. Kondo shows that the maxillary and mandibular arch is highly adaptive and arch expansion is an alternative decision to make before extraction. With incompetent lip closure and lips anterior to the e-line, extraction is contemplated³⁷. For most patients, non-extraction treatment can be achieved by opting for molar-oriented orthodontics³⁸.

In the editorial of "The Angle Orthodontist", Turpin stated that the two-phase treatment and starting treatment earlier is the primary reason for the increase of non-extraction treatment³⁹. Reasons for fewer extractions are different aesthetic guidelines, long-term studies of stability, concern for temporomandibular dysfunction, and technique changes⁴⁰. If possible, Gianelly prefers to initiate treatment in the late mixed-dentition stage⁴¹. By saving the leeway space in the mandibular arch, three-quarters of all individuals have adequate space to accommodate an aligned dentition and a non-extraction strategy can be pursued in the vast majority of patients simply by preserving arch length. According to Soejima et al, a policy of non-extraction was pursued in a higher proportion of patients for whom treatment began in mixed dentition than in those where it started in permanent dentition⁴². In orofacial orthopaedics, it is crucial to include the neuromuscular function as a causal factor of crowding. A constriction of the arch is in connection with the constriction of the neuromuscular matrix⁴³. As demonstrated in this article, early intervention can help to avoid extraction and to build up a symmetric arch, especially in young patients with a unilateral loss of arch length due to the early loss of a baby tooth.

Since 2009, Align Technology has offered a new product designed especially for teenagers with the Invisalign Teen product. Advantages of the Invisalign System compared with a fixed multibracket treatment are that it provides an aesthetic, more flexible way to give teenagers the option to align teeth. The aligners are comfortable and removable, allowing for normal tooth brushing and oral hygiene. The clear aspect is almost invisible, which allows teenagers an



Figs 1 a to d Initial examination: Bite after premature loss of teeth 55, 65 and 75. Especially in the maxilla, the first molars show mesial rotation and a reduced Leeway space.

Fig 2 Panoramic view from the beginning of the treatment. After the premature loss of teeth 55 and 65, the maxillary first molars have migrated mesial and with this, reduced significantly the space for the eruption of the permanent second premolars.

orthodontic treatment without further restrictions, irritations and self-consciousness – all often associated with brackets and wires. Also, Invisalign Teen offers young patients whose adult teeth have not all yet erupted, special features such as blue wear-indicators to show the amount of wearing time of the aligners, eruption tools for the eruption of canines, second premolars and second molars, as well as six free individual replacement aligners in case these are lost or misplaced.

As we have had excellent experience with cooperative teenage patients at our office in recent years, we decided to treat even the youngest patients in the mixed dentition, starting in 2004 with special permission from Align Technology and the American Food and Drug Administration (FDA) to treat even young children in the early and mixed dentition⁴⁴. Despite this young age, treatments achieved similar results as with the previously used removable orthodontic appliances, but with more comfort for patients.

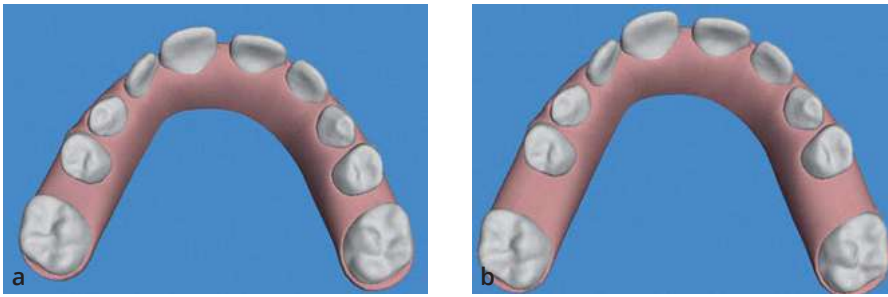
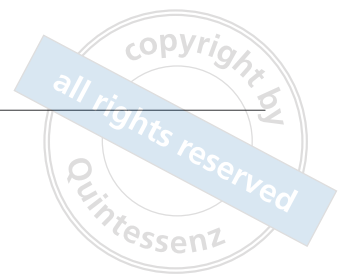Publications have reported on the tipping tendency of upper molars in cases where baby teeth have been lost prematurely without retention, leading to decreased space for the eruption of permanent premolars and, therefore, a possible future need for extraction⁴⁵. The possibility to facilitate

tooth eruption with a comfortable, removable and aesthetic appliance such as the Invisalign System is an easy way to pre-treat in the mixed dentition. After years of treating mixed dentition patients with the Invisalign System we have not seen an increased presence of external apical root resorption or disruption of tooth apex formation after treatment.

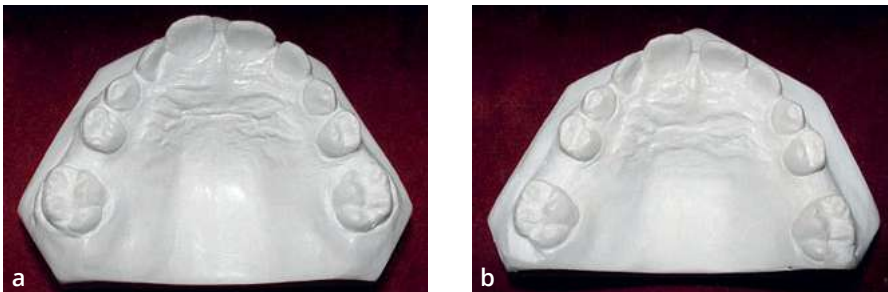
This article will describe several examples of the Invisalign Teen System being used to treat young children; firstly to create space for the eruption of the permanent teeth and avoiding the potential need for sequential extractions.

Patient 1

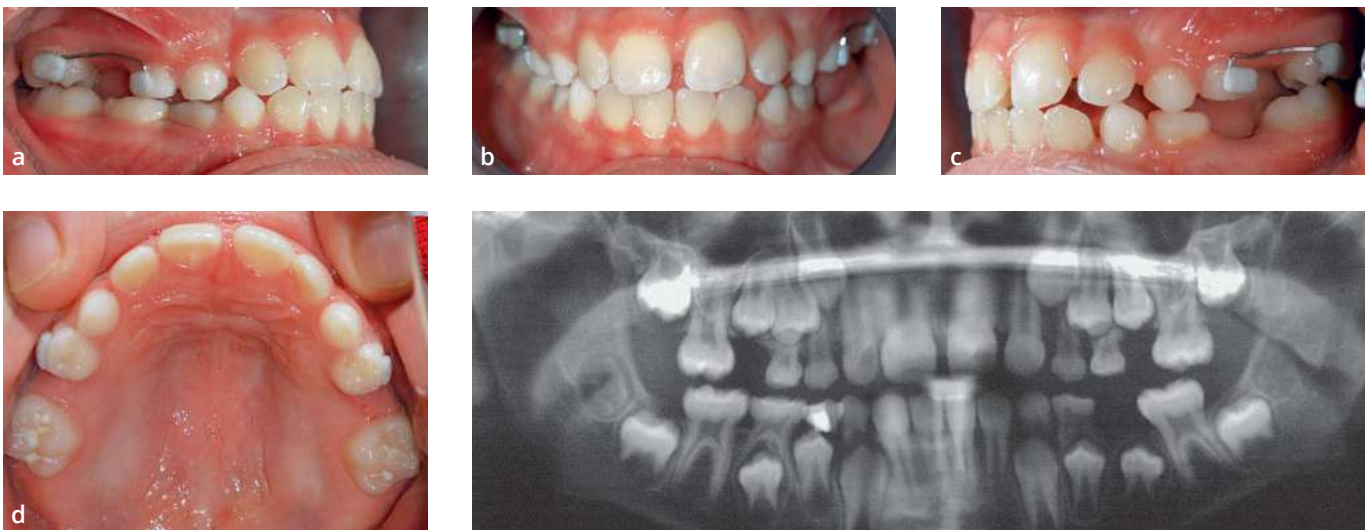
Initially, the Invisalign System was only licensed for the treatment of adults with fully erupted teeth. With an extraordinary FDA licence in 2003, we were able to treat the first child with the Invisalign System at just 7 years and 10 months. After early extraction of teeth 55 and 65 in the early dentition, the patient had experienced a considerable migration and mesial rotation of the first molars in the maxilla due to her practitioner's failure to recommend a retention appliance (Figs 1 and 2).



Figs 3a and b a) Initial situation of the maxilla in the ClinCheck Software, and b) treatment goal, planned with distalization of the maxillary first molars.



Figs 4a and b a) Maxillary casts at the start of Invisalign treatment, and b) after gap opening with the Invisalign System and distalization of maxillary first molars.



Figs 5a to d Final findings: As a gap holder for the eruption of the maxillary second premolars, we bonded partial arches made of 16 × 22 steel serve buccally on first premolars and permanent molars.

Fig 6 Panoramic layer view after Invisalign treatment: The maxillary first molars show good axial inclination. The unimpeded eruption of the teeth 15 and 25 can be expected shortly.

The derotation of the molars was performed with a Quadhelix appliance; the further distalization of the molars was planned with the Invisalign System. Based on the ClinCheck Software (Fig 3), treatment included 14 aligners. To obtain quicker results at that time, the wearing time of each aligner was reduced to 9 days instead of 14. Today, due to the new SmartTrack aligner material, changing every 7 days or even less in young patients is reasonable and

possible. After Invisalign treatment, the intraoral situation shows the distalized molars, and that spaces have been opened sufficiently for the eruption of teeth 15 and 25 (Figs 4 and 5). Stainless steel sectional wires were bonded buccally to the maxillary first molars and primary teeth 54 and 64 for retention (Fig 5). Teeth 16 and 26 showed a correct axial inclination in the orthopantomogram (Fig 6). After several years, the patient returned to our office for a control

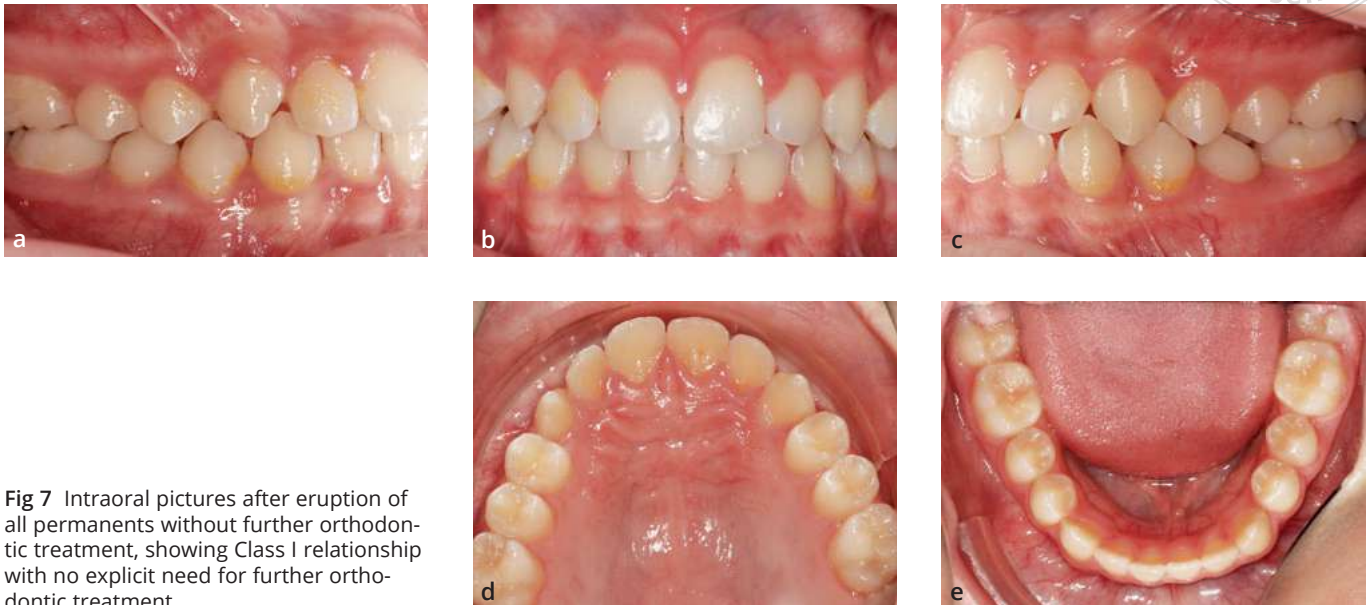


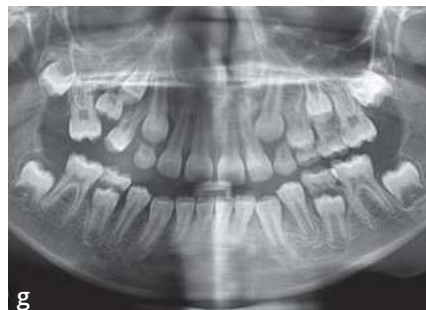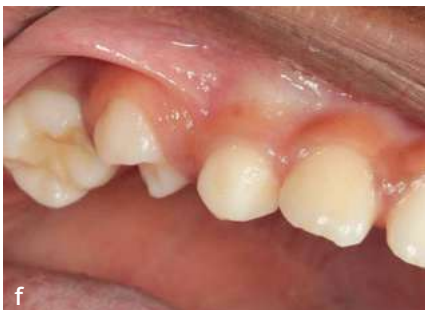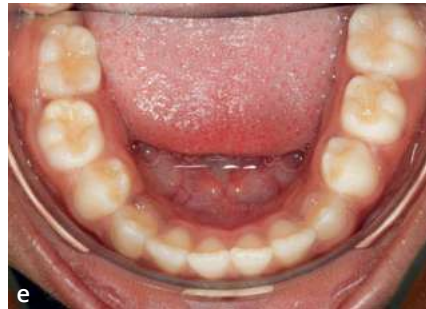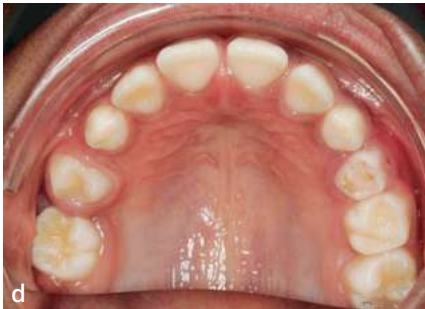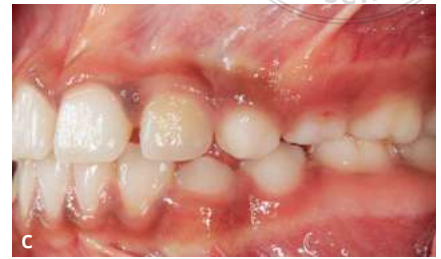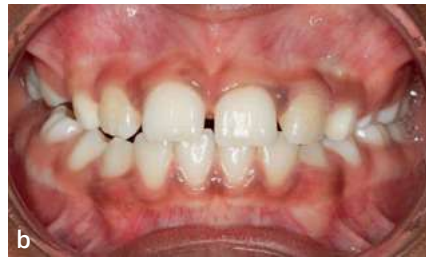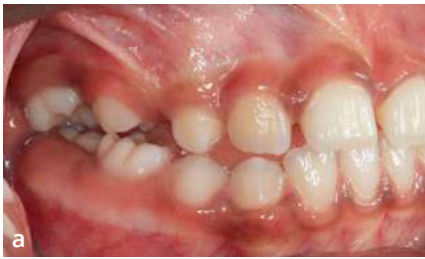Fig 7 Intraoral pictures after eruption of all permanents without further orthodontic treatment, showing Class I relationship with no explicit need for further orthodontic treatment.

appointment, showing a full permanent dentition (Fig 7). Teeth 15 and 25 had erupted perfectly and the patient showed harmonious arches in Class I relationship. Further orthodontic treatment was not needed. Without the distalization performed with the Invisalign System, extractions might have been inevitable.

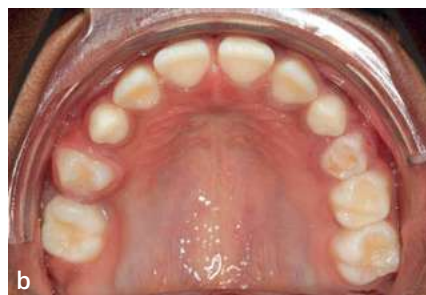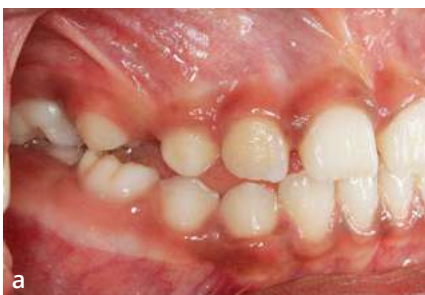Patient 2

The second patient came to our orthodontic office at the age of 8. The maxillary arch showed a mesially tipped tooth 16 and a distally migrated tooth 14, with insufficient space for the eruption of tooth 15 (Figs 8a to g). The orthopantomogram showed the amount of tipping of tooth 16 and revealed a retained and displaced tooth 55 (Fig 8g). Due to the mesial inclination of the tooth crown 16, the gingiva was covering a large amount of the dental mesial surface, and due to this fact it was especially impossible for the aligners to cover the mesial aspect or the entire tooth crown (Fig 8f). To get sufficient anchorage for the molar uprighting and to optimise the aligner grip, we decided to add tooth 16 composite on the mesial occlusal surface (Figs 9a and b). This way we aimed to increase the mesial surface of the tooth crown and obtain better anchorage for the uprighting movement for the aligner. A vertical rectangular attachment

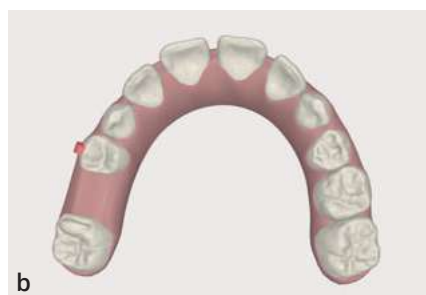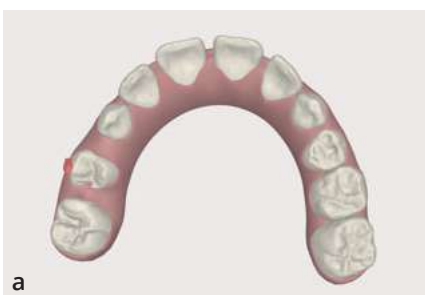was planned on tooth 14 for better anchorage (Fig 10). The first aligner set consisted of 17 maxillary aligners, which the patient changed every 10 days, distalizing tooth 16 and mesializing tooth 14 (Figs 10a and b). After this phase, a second phase for refinement began (Figs 11a to e), adding a vertical rectangular attachment also on tooth 16 to obtain better anchorage for uprighting of crown 16, using additional 16 maxillary aligners. Figures 12a and 12b show a comparison of the ClinCheck Software situation after the first phase of treatment and with the planned outcome. Figures 13a and 13b show the intraoral situation after a second treatment phase, with the composite build-up still bonded on the mesial surface of tooth 16. The patient demonstrated perfect aligner fitting throughout the treatment, with good compliance, as shown in Figures 13c and 13, which show the intraoral situation with the aligner *in situ*. The situation after removal of composite on tooth 16 is shown in Figure 13; tooth 16 has been uprighted and distalized, tooth 14 mesialized, and with this we created sufficient space for the eruption of tooth 15 (Fig 14). The patient was advised to continue wearing the aligner at night to maintain the space and retain the achieved situation. The patient was referred to the dental surgeon and tooth 55 was removed surgically. The intraoral situation shows further natural eruption of tooth 15 into the gained space; in the following months, the aligner treatment was continued for the finishing (Fig 15).



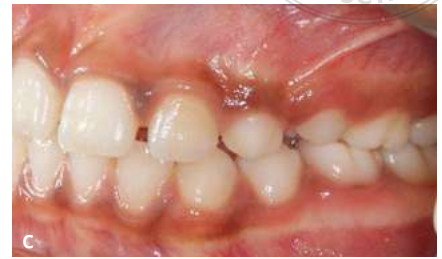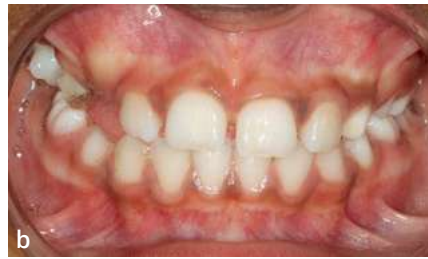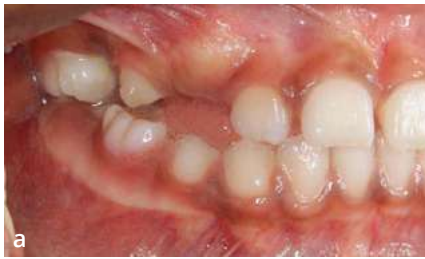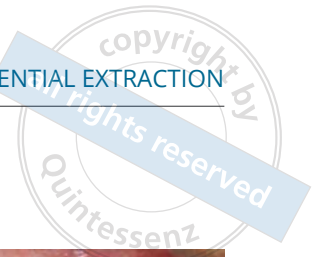Figs 8a to g Intraoral situation and orthopantomogram at the start of treatment. Mesial tipped tooth 16 and distally migrated tooth 14 with insufficient space for eruption of tooth 15 (f). Orthopantomogram showing the amount of tipping of tooth 16 and a retained and displaced tooth 55 (g).



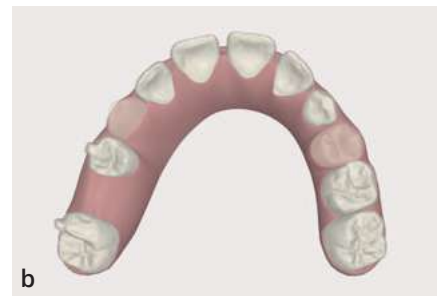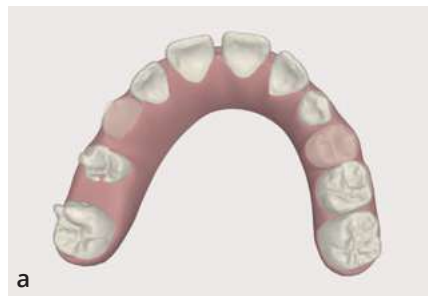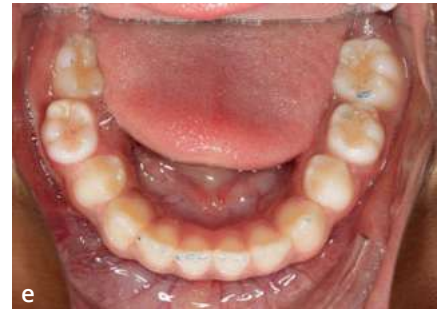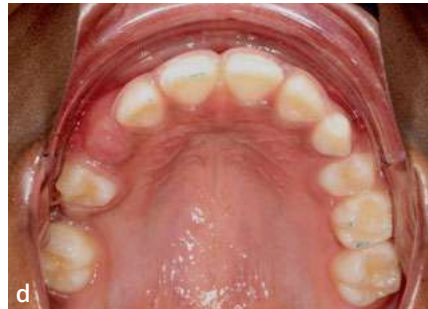Figs 9a and b Intraoral situation with composite added on the mesial surface of tooth 16 for better anchorage of aligners.



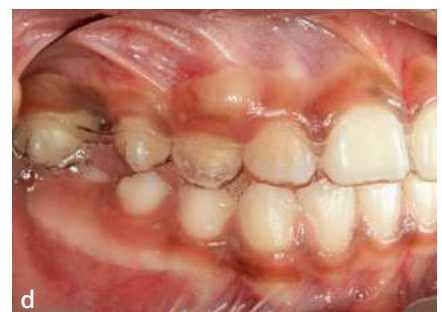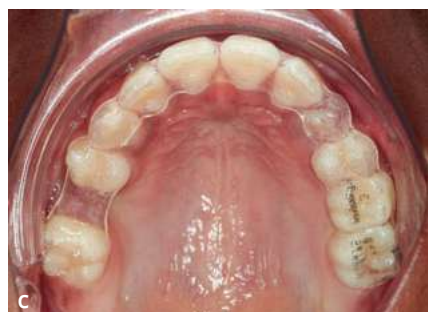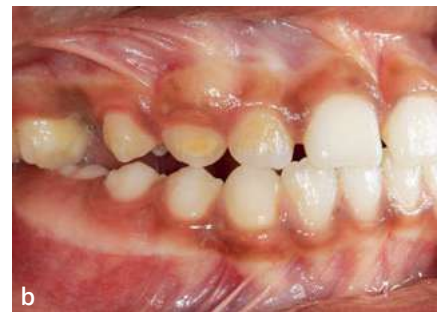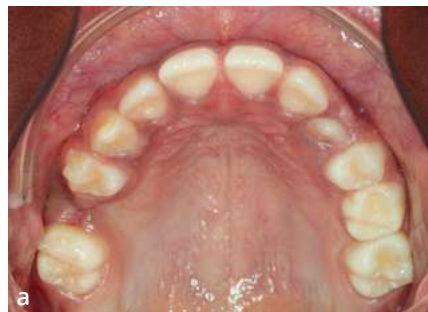Figs 10a and b a) Situation in the ClinCheck Software at the start of treatment, and b) the final planned outcome with distalization and tipping of mesial inclined crown 16 to distal and mesialisation of tooth 14 (with an added conventional vertical rectangular attachment on 14) to open sufficient space for eruption of tooth 15.



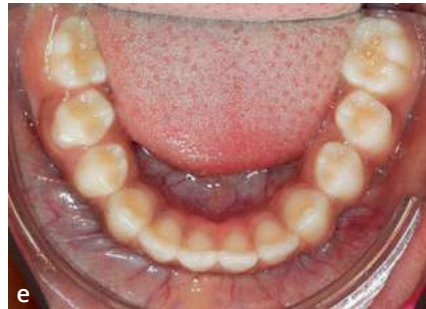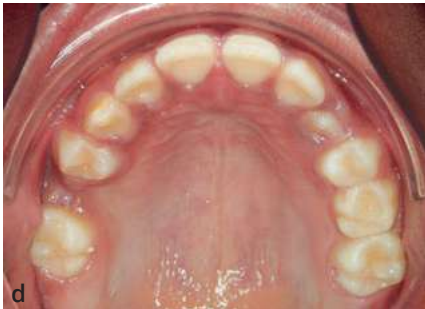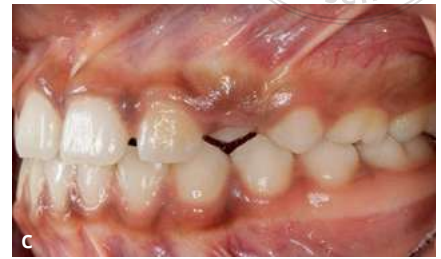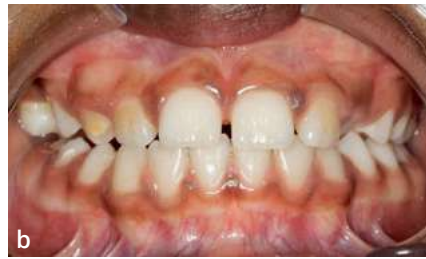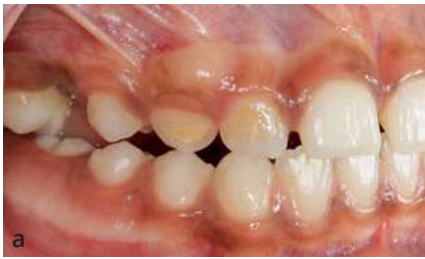Figs 11a to e Course of treatment: Intraoral situation with the start of the second phase of treatment; a vertical rectangular attachment was added also on tooth 16 for increased anchorage for the further space opening.



Figs 12a and b a) Situation after the first phase, and b) the planned outcome in the ClinCheck Software.



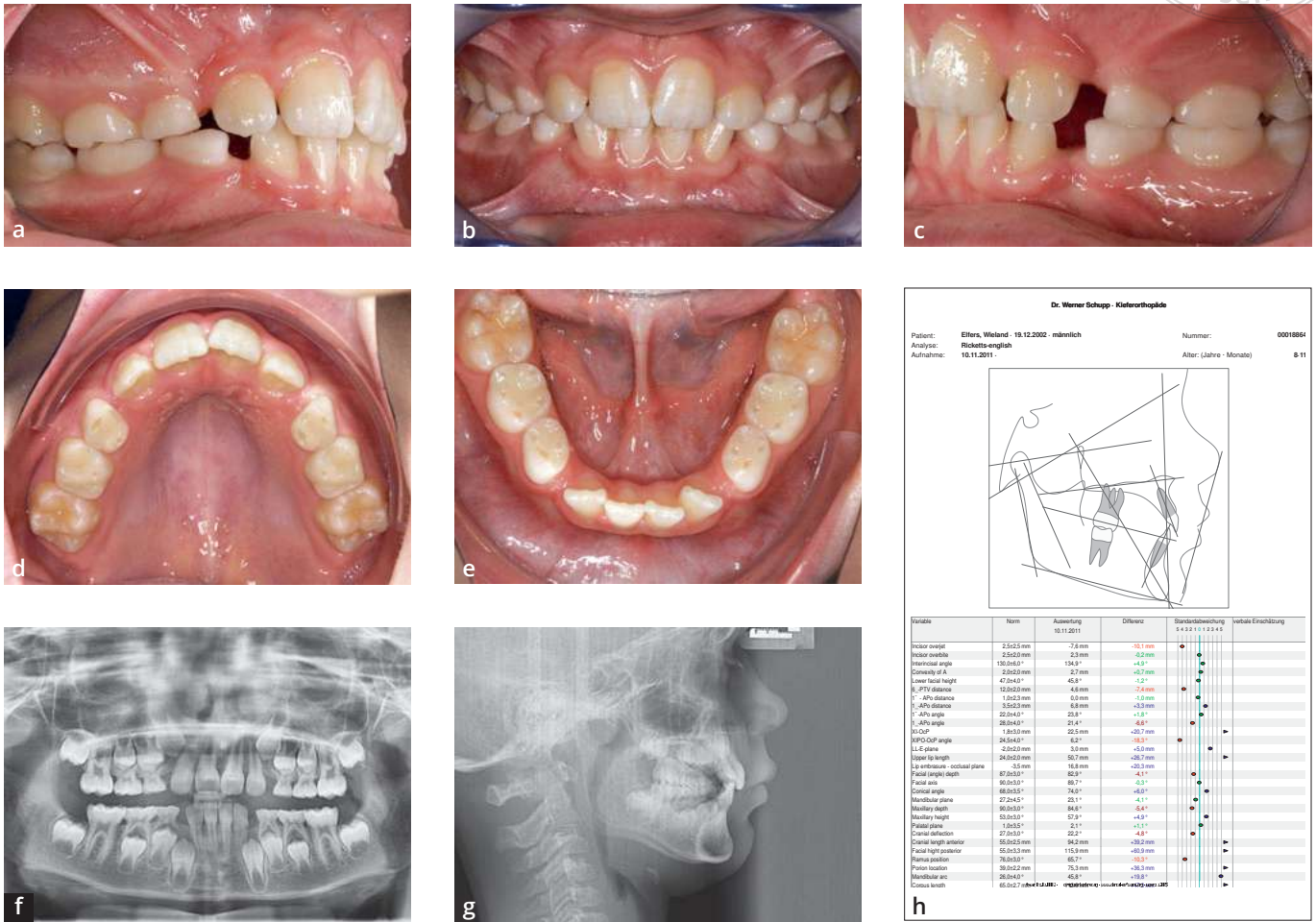
Figs 13a to d a and b) Final situation after the second phase with composite still on tooth 16; c and d) the intraoral situation with the aligner *in situ* with eruption tabs on teeth 13, 23 and good aligner fitting.



Figs 14a to e Intraoral situation after removal of composite on tooth 16 and sufficient space for eruption of tooth 15.

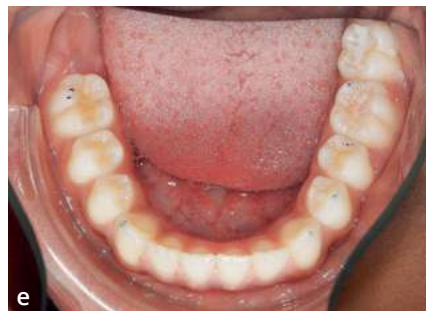
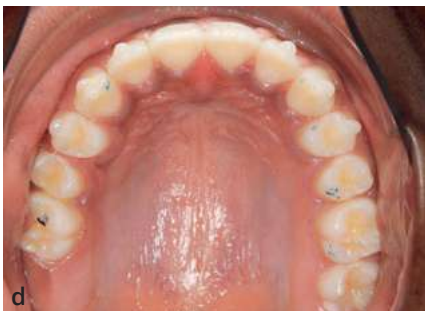
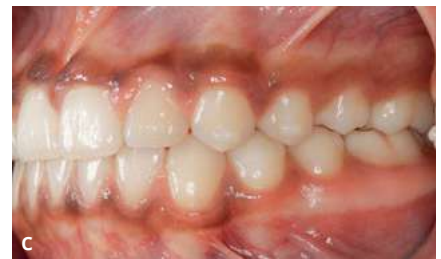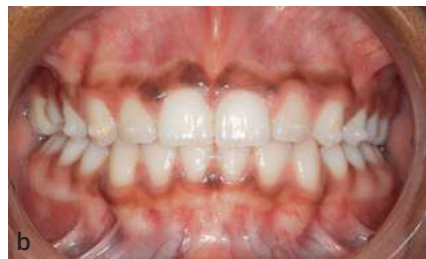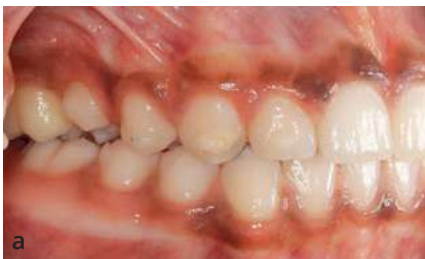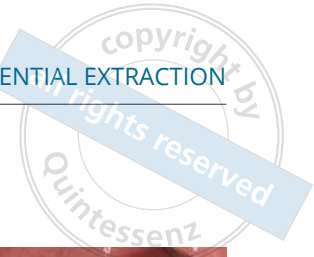Fig 15 Intraoral situation after further eruption of tooth 15 and continued treatment for finishing.

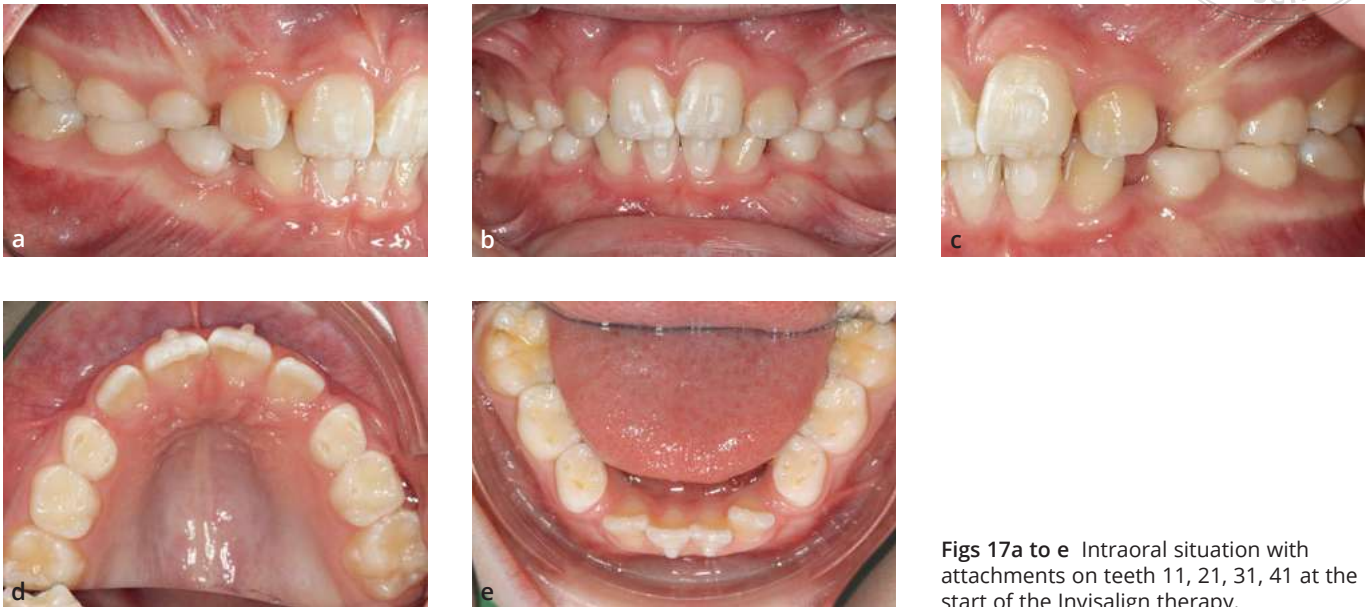

Figs 16a to h a) to e) Intraoral situation at the start of treatment planning at the age of 9 years with insufficient space for the eruption of upper and lower canines; f) orthopantomogram, and g and h) lateral radiograph with values according to Ricketts.

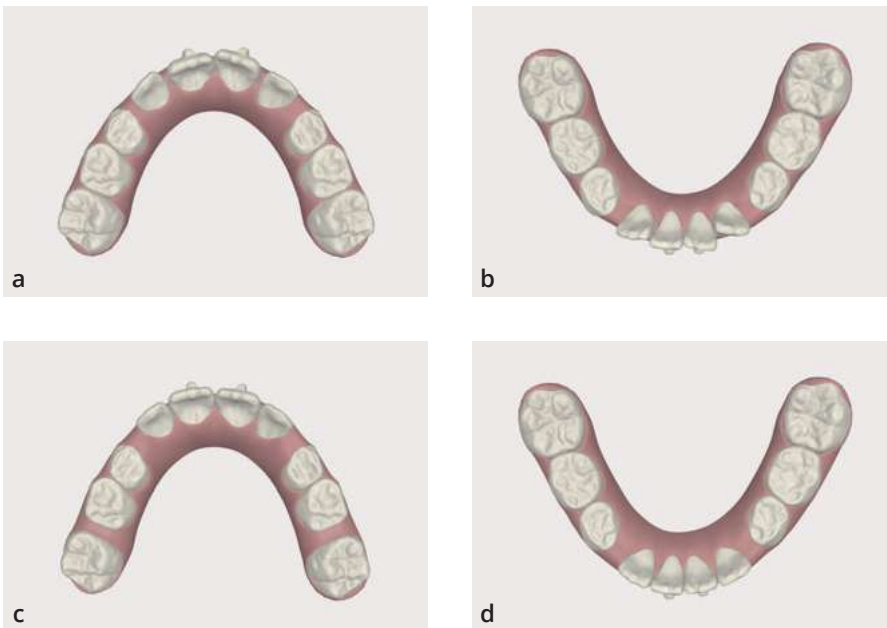
Patient 3

The third patient example shows a young boy visiting our office at the age of 11 with insufficient space for the eruption of maxillary and mandibular canines due to the premature loss of baby teeth (Figs 16a to h). An orthodontic treatment plan suggested to the patient and its parents involved a multibracket appliance to open up space for the eruption of the canines, or a premolar extraction in both arches to obtain sufficient space to align the arches and allow eruption of canines. We offered the patient an alternative therapy of treatment with the Invisalign System. To create space for the erupting canines we aimed for distalization of permanent molars in the maxillary arch and anterior protrusion in both arches. In this patient, we did not plan to move

any deciduous teeth with the aligners, but to gain the space needed by protruding the mandibular anteriors and distalizing the maxillary molars to increase the Leeway space. The patient chose Invisalign therapy, and the first phase began with 32 upper and 33 lower aligners. Attachments were bonded for anchorage and for angulation on maxillary central incisors and mandibular central incisors according to the conventional rectangular attachments. The patient changed the aligners every 10 days. Figures 17a to e show the intraoral situation at the start of treatment. Figures 18a to 18d show the initial and final planned situation in the ClinCheck Software. After 12 months of treatment, the first phase was finished and the patient wore removable retainers to allow for further eruption of the canines. However, the patient was not wearing mandibular anterior region



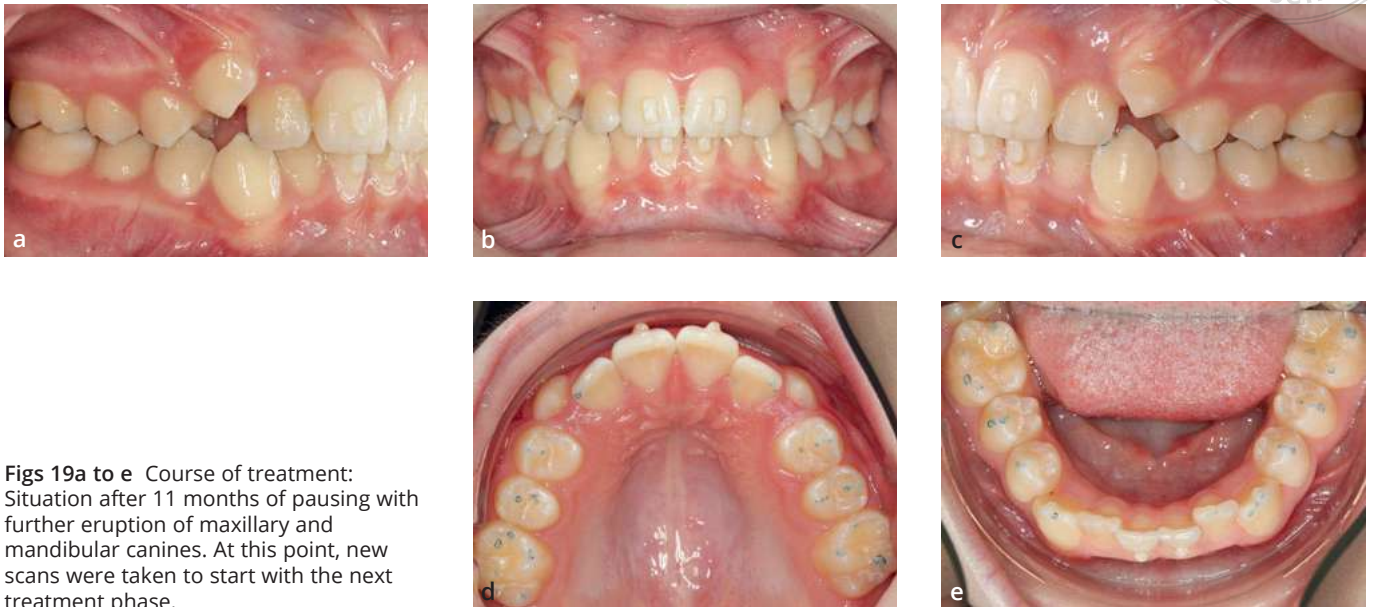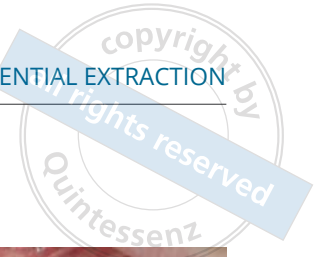Figs 17a to e Intraoral situation with attachments on teeth 11, 21, 31, 41 at the start of the Invisalign therapy.



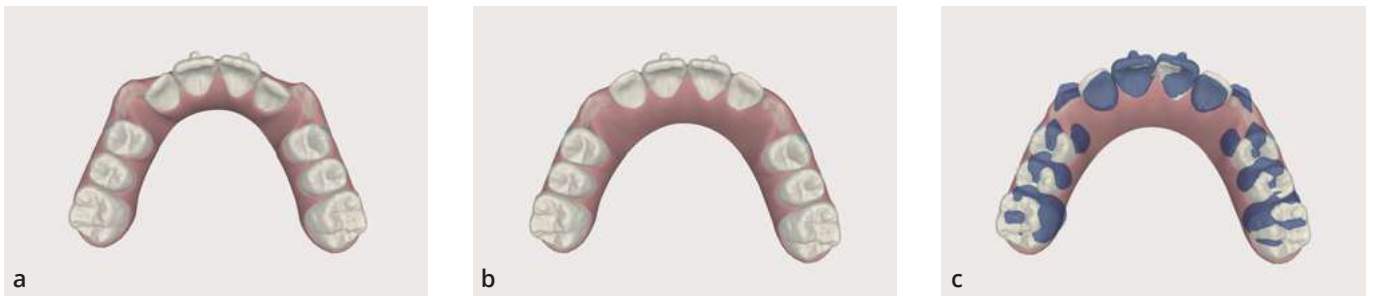Figs 18 a and b) The ClinCheck Software shows the maxillary and mandibular initial situation, and c and d) the final planned situation with distalization of maxillary molars and slight anterior protrusion and alignment with increased space opening for eruption of maxillary and mandibular canines.

(Figs 19a to e). After an 11-month wait and further tooth eruption, new scans for the next treatment phase were taken. This second phase included 28 maxillary and 21 mandibular aligners with distalization in the maxillary arch with Class II elastics and eruption tabs for maxillary canines (Figs 20a to c). A final refinement was performed (Figs 21a to e) with 13 aligners to align the arches and to finalise the correct canine position in a Class I relationship, also using

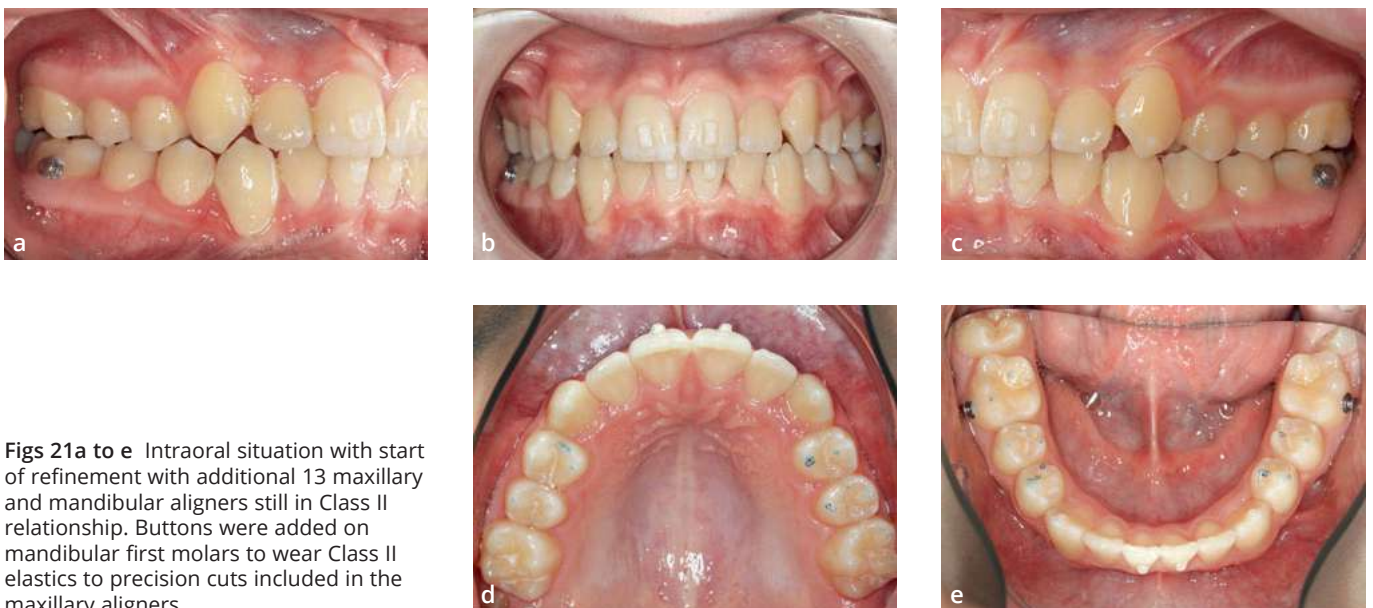
the bite jump simulation in the ClinCheck Software with advancement of the mandible to end in a perfect Class I relationship simulating the Class II elastic effect (Figs 22a to c). After 3 years, we removed the attachments and inserted an upper removable aligner, together with a lingual fixed retainer from tooth 33 to tooth 43 for retention (Figs 23a to g). No further lateral radiograph was taken as in Germany, the medical grounds for justification under the Ordinance



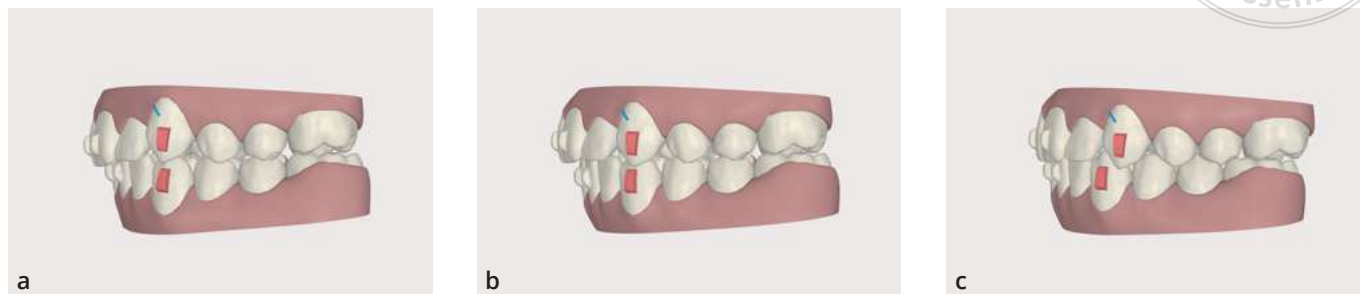
Figs 19a to e Course of treatment: Situation after 11 months of pausing with further eruption of maxillary and mandibular canines. At this point, new scans were taken to start with the next treatment phase.



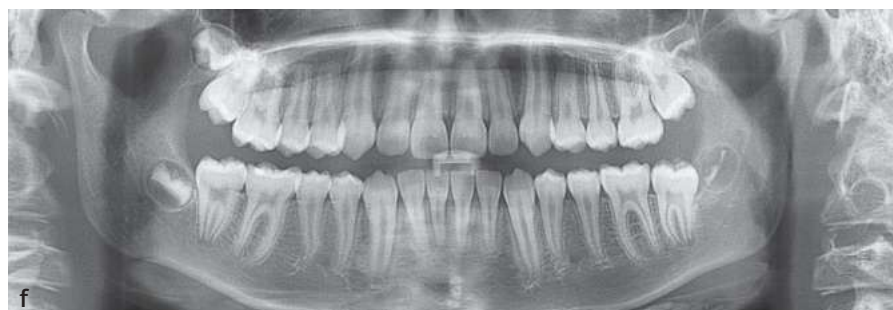
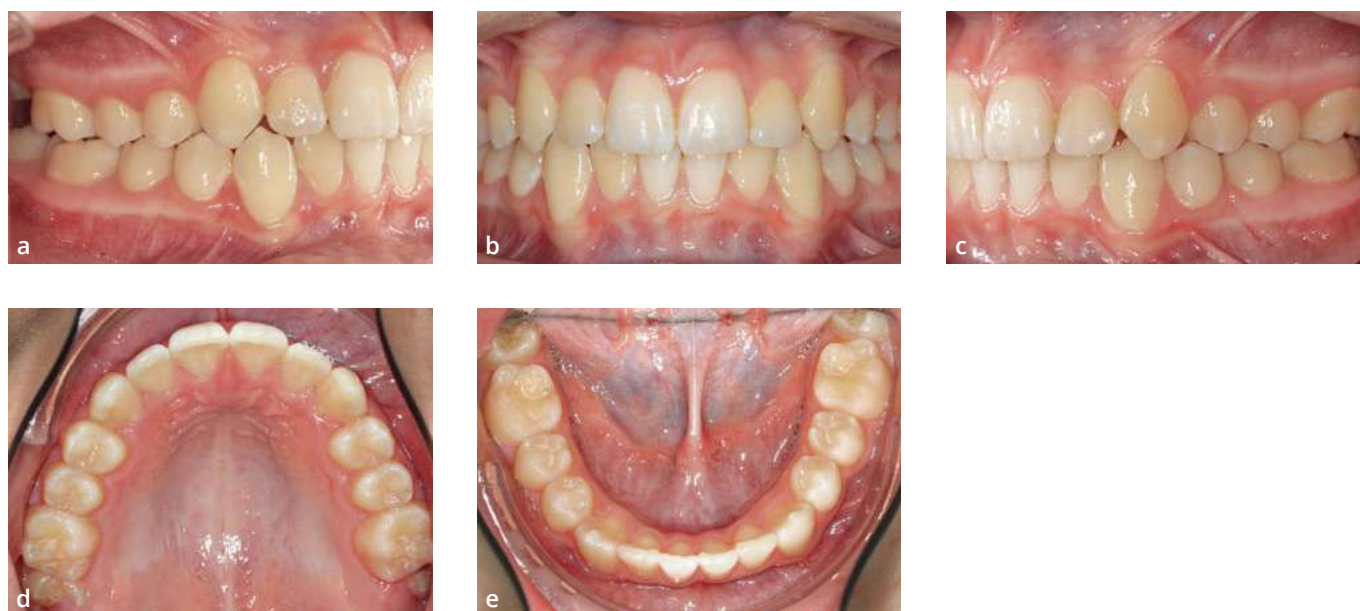Figs 20a to c a) Situation in the ClinCheck Software at the start of second phase of treatment with eruption tabs for teeth 13, 23; b) final situation after 28 maxillary aligners, and c) superimposition of planned movements (blue colour actual situation, white colour planned final situation).



Figs 21a to e Intraoral situation with start of refinement with additional 13 maxillary and mandibular aligners still in Class II relationship. Buttons were added on mandibular first molars to wear Class II elastics to precision cuts included in the maxillary aligners.



Figs 22a to c a) Situation in the ClinCheck Software at the start of refinement in Class II relationship and additional vertical rectangular attachments on canines; b) after 13 aligners with alignment of the arches, and c) after simulation of mandibular bite jump due to Class II elastics into a Class I relationship.

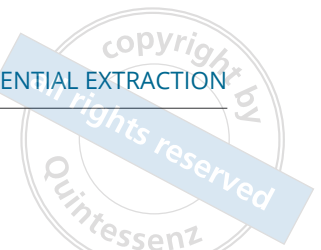

Figs 23a to f a to e) Final intraoral situation in Class I relationship; f) orthopantomography without pathologies, wisdom teeth advised for further control.

on the Protection of X-Ray Radiation (X-Ray Regulation of the Federal Republic of Germany) is not permitted for forensic reasons alone. The orthopantomogram showed no pathologies (Fig 23f), and we advised the patient to undergo further future control of his wisdom teeth.

Conclusion

Early intervention in patients with premature loss of baby teeth and reduced space for permanent eruption can help to avoid extractions. The Invisalign System allows a



comfortable way to treat even the youngest patients and create sufficient space for tooth eruption in the mixed dentition and afterwards in the permanent dentition. The Invisalign Teen product was especially designed for the erupting dentition and therefore offers an ideal treatment option for younger patients. Despite often-described motivation issues with younger patients, our experience is positive with the removable aligners – hygiene is significantly better without fixed appliances and the patients are happy with the aesthetics.

Frequent controls and motivation discussions are necessary and advisable, as with any other device used by young patients. There seems to be no significant difference in motivating 8 to 10-year-old patients compared with 13 to 15-year-old patients, except for teenagers' often-difficult puberty phases. According to the good compliance and bone remodelling of young patients, a 7-day aligner change seems to be appropriate. Starting treatments as young as 8 to 10 years with the first of a two-phase treatment, followed by a pause to allow full eruption and a second phase for finishing, can help to avoid extractions, as shown in the patient examples. A further increase of time of the actual 5-year limit range for additional aligners could also be an option in future to avoid further costs and obtain optimal treatment possibilities in young patients with the Invisalign System.

References

- Boyd RL. Esthetic orthodontic treatment using the Invisalign appliance for moderate to complex malocclusions. *J Dent Educ* 2008;72:948–967.
- Giancotti A, Mampieri G. Unilateral canine crossbite correction in adults using the Invisalign method: a case report. *Orthodontics (Chic.)* 2012;13:122–127.
- Schupp W, Haubrich J, Neumann I. Class II Correction with the Invisalign system. *J Clin Orthod* 2010;44:28–35.
- Giancotti A, Mampieri M, Greco M. Correction of deep bite in adults using the Invisalign system. *J Clin Orthod* 2008;42:719–726.
- Harnick DJ. Using clear aligner therapy to correct malocclusion with crowding and an open bite. *Gen Dent* 2012;60:218–223.
- Schupp W, Haubrich J, Neumann I. Treatment of anterior open bite with the Invisalign system. *J Clin Orthod* 2010;44:501–507.
- Schupp W, Haubrich J. Möglichkeiten und Grenzen der Invisalign Therapie. *Quintessenz, Kieferorthopädie* 2010;61:951–962.
- Zawawi KH. Orthodontic treatment of a mandibular incisor extraction case with invisalign. *Case Rep Dent* 2014;2014:657657.
- Hönn M, Göz G. A premolar extraction case using the Invisalign system. *J Orofac Orthop* 2006;67:385–394.
- Simon M, Keilig R, Schwarze J, Jung BA, Bourauel C. Treatment outcome and efficacy of an aligner technique—regarding incisor torque, premolar derotation and molar distalization. *BMC Oral Health* 2014;14:68.
- Castroflorio T, Garino F, Lazzaro A, Debernadi C. Upper-incisor root control with Invisalign appliances. *J Clin Orthod* 2013;47:346–351.
- Mampieri G, Giancotti A. Invisalign technique in the treatment of adults with pre-restorative concerns. *Prog Orthod* 2013;14:40.
- Schwartz B. Invisalign and aesthetic dentistry. *N Y State Dent J* 2012;78:36–37.
- Schupp W, Haubrich J, (eds). *Aligner Orthodontics*. Quintessenz Berlin, 2015.
- Womack WR, Day RH. Surgical-orthodontic treatment using the Invisalign system. *J Clin Orthod* 2008;42:237–245.
- Schupp W, Haubrich J, Hermens E, Boisserée W. Diagnose und Therapie des kranio-mandibulären und muskuloskeletalen Systems in der kieferorthopädischen Praxis unter besonderer Berücksichtigung des Invisalign Systems. *Inf Orthod Kieferorthop* 2013:93–103.
- Schupp W, Haubrich J, Neumann I. Invisalign treatment of patients with craniomandibular disorders. *Int Orthod* 2010;8:253–267.
- Miller DB. Invisalign in TMD treatment. *Int J Orthod Milwaukee*, 2009;20:15–19.
- Lin JC, Tsai SJ, Liou EJ, Bowman SJ. Treatment of challenging malocclusions with Invisalign and miniscrew anchorage. *J Clin Orthod* 2014;48:23–36.
- Giancotti A, Germano F, Muzzi F, et al. A miniscrew-supported intrusion auxiliary for open-bite treatment with Invisalign. *J Clin Orthod* 2014;48:348–358.
- Rossini G, Parrini S, Castroflorio T, Deregibus A, Debernardi CL. Periodontal health during clear aligners treatment: a systematic review. *Eur J Orthod* 2015;37:539–543.
- Levrini L, Mangano A, Montanari P, Margherini S, Caprioglio A, Abbate GM. Periodontal health status in patients treated with the Invisalign system and fixed orthodontic appliances: A 3 months clinical and microbiological evaluation. *Eur J Dent* 2015;9:404–410.
- White DW, Julien KC, Jacob H, Campbell PM, Buschang PH. Discomfort associated with Invisalign and traditional brackets: A randomized, prospective trial. *Angle Orthod*, 2017;87:801–808.
- Azaripour A, Weusmann J, Mahmoodi B, et al. Braces versus Invisalign: gingival parameters and patients' satisfaction during treatment: a cross-sectional study. *BMC Oral Health*, 2015;15:69.
- Nedwed V, Miethke RR. Motivation, acceptance and problems of Invisalign patients. *J Orofac Orthop* 2005;66:162–173.
- Abbate GM, Caria M, Montanari C, et al. Periodontal health in teenagers treated with removable aligners and fixed orthodontic appliances. *J Orofac Orthop* 2015;7:240–250.
- Fujiyama K, Honjo T, Suzuki M, Matsuoka S, Deguchi T. Analysis of pain level in cases treated with Invisalign aligner: comparison with fixed edgewise appliance therapy. *Prog Orthod* 2014;15:64.
- Weintraub JA, Vig PS, Brown C, Kowalski CJ. The prevalence of orthodontic extractions. *Am J Orthod Dentofacial Orthop* 1989;96:462–466.
- Peck S, Peck H. Frequency of tooth extraction in orthodontic treatment. *Am J Orthod* 1979;76:491–496.
- Baumrind S, Korn EL, Boyd RL, Maxwell R. The decision to extract: part II. Analysis of clinicians' stated reasons for extraction. *Am J Orthod Dentofacial Orthop* 1996;109:393–402.
- Xu TM, Liu Y, Yang MZ, Huang W. Comparison of extraction versus non-extraction orthodontic treatment outcomes for borderline Chinese patients. *Am J Orthod Dentofacial Orthop* 2006;129:672–677.
- Stephens CK, Boley JC, Behrents RG, Alexander RG, Buschang PH. Long-term profile changes in extraction and nonextraction patients. *Am J Orthod Dentofacial Orthop* 2005;128:450–457.
- Kim E, Gianelly AA. Extraction vs nonextraction: arch widths and smile aesthetics. *Angle Orthod* 2003;73:354–358.



34. Freitas KMS, de Freitas MR, Henriques JFC, Pinzan A, Janson G. Postretention relapse of mandibular anterior crowding in patients treated without mandibular premolar extraction. *Am J Orthod Dentofacial Orthop* 2004;125:480–487.
35. Zafarmand AH, Qamari A, Zafarmand MM. Mandibular incisor re-crowding: is it different in extraction and non-extraction cases? *Oral Health Dent Manag* 2014;13:669–674.
36. Little RM, Riedel RA, Engst ED. Serial extraction of first premolars--postretention evaluation of stability and relapse. *Angle Orthod* 1990;60:255–262.
37. Ileri Z, Basciftci FA, Malkoc S, Ramoglu SI. Comparison of the outcomes of the lower incisor extraction, premolar extraction and non-extraction treatments. *Eur J Orthod* 2012;34:681–685.
38. Arimoto H, Kaku J, Sinohara N, eds. *Hibasshi Kyouseichiryou - Molar oriented Orthodontics - No Jissai*. Ishiyaku Publishers, 2011.
39. Turpin DL. Percentage swings in extraction frequencies. *Angle Orthod* 1994;64:403.
40. Proffit WR. Forty-year review of extraction frequencies at a university orthodontic clinic. *Angle Orthod* 1994;64:407–414.
41. Gianelly AA. Crowding: timing of treatment. *Angle Orthod* 1994;64:415–418.
42. Soejima U, Motegi E, Nomura M, Yamazaki M, Sueishi K. Change in proportion of extraction and non-extraction in orthodontic patients. *Bull Tokyo Dent Coll* 2014;55:225–231.
43. Frankel C, Frankel R (eds). *Der Funktionsregler in der orofazialen Orthopädie*. Hüthig:Heidelberg, 1992.
44. Neumann I, Schupp W, Heine R. Distalbewegung oberer 1. Molaren mit dem Invisalign-System- ein Patientenbericht. *Kieferorthopädie* 2004;2:133–137.
45. Cernei ER, Maxim DC, Zetu IN. The influence of premature loss of temporary upper molars on permanent molars. *Rev Med Chir Soc Med Nat Iasi* 2015;119:236–242.